

Caso clinico

Acute psychiatric presentation of steroid-responsive encephalopathy: the underrecognized side of autoimmune thyroiditis

Sintomatologia psichiatrica acuta quale manifestazione di encefalopatia sensibile agli steroidi: l'aspetto misconosciuto della tiroidite autoimmune

CRISTIANO CARLONE, LILIANA TODINI, ISABELLA MARINI, MICHELE MAJORANA, SARA CASCIATO, ANNA TERESA GIALONARDO, MAURO PALLAGROSI, MASSIMO SALVIATI, MASSIMO BIONDI

E-mail: cristiano.carlone@hotmail.it

Department of Neuroscience, Sapienza University of Rome, Italy

SUMMARY. Steroid-responsive encephalopathy associated with autoimmune thyroiditis (SREAT), also known as Hashimoto encephalopathy, represents a rare disorder of presumed autoimmune origins that can be diagnosed when a protean variety of psychiatric symptoms are present in association with elevated titers of anti-thyroid antibodies. Symptoms can have a rapid and complete remission with corticosteroid treatment. A 19-year-old girl, with clinical history of Basedow-Graves disease, has been admitted to our department after presenting acute psychiatric symptomatology. Clinical and serological findings were used to formulate the diagnosis of SREAT, confirmed by subsequent positive response to corticosteroid treatment. SREAT can mimic an acute psychiatric symptomatology, thus it seems extremely relevant for psychiatrists to consider this syndrome in differential diagnosis algorithm, especially in those patients presenting a history of autoimmune thyroid disorder, in order to ensure adequate diagnosis and treatment.

KEY WORDS: Hashimoto encephalopathy, steroid responsive encephalopathy associated with autoimmune thyroiditis, Basedow-Graves disease, autoimmune thyroiditis, Brief Psychiatric Rating Scale.

RIASSUNTO. L'encefalopatia sensibile agli steroidi associata a tiroidite autoimmune (SREAT), nota anche come encefalopatia di Hashimoto, rappresenta una rara patologia di presunta origine autoimmune che può venire diagnosticata in presenza di sintomi psichiatrici tipicamente proteiformi associati ad elevati titoli di anticorpi anti-tiroidei. Il trattamento con corticosteroidi è efficace nel conseguire una remissione rapida e completa della sintomatologia. Una giovane donna di 19 anni, con storia clinica di malattia di Basedow-Graves, è stata ricoverata presso il nostro dipartimento per sintomatologia psichiatrica acuta e, sulla base dei reperti clinici e sierologici, è stata posta diagnosi di SREAT, confermata dalla successiva risposta positiva al trattamento corticosteroidico. La SREAT può mimare i sintomi di una patologia psichiatrica acuta, è quindi estremamente importante che lo psichiatra prenda di considerazione questa sindrome nell'algoritmo di diagnosi differenziale, soprattutto in quei pazienti che presentano storia di tiroidite autoimmune, al fine di assicurare un'adeguata diagnosi e un trattamento tempestivo.

PAROLE CHIAVE: encefalopatia di Hashimoto, encefalopatia sensibile agli steroidi associata a tiroidite autoimmune, malattia di Basedow-Graves, tiroidite autoimmune, Brief Psychiatric Rating Scale.

INTRODUCTION

Steroid-responsive encephalopathy associated with autoimmune thyroiditis (SREAT) is a syndrome which probably belongs to the group of autoimmune encephalopathies, a heterogeneous group of central nervous system inflammations that most of the time are not easily differentiable from the infectious forms. The clin-

ical presentation consists of relapsing and remitting episodes of neurological or psychiatric symptoms, which remit after corticosteroid treatment (1,2), or, in corticosteroid-resistant patients, after immunosuppressive therapy, intravenous immunoglobulins or plasmapheresis (3). It might represent a clinical presentation of reversible dementia. Crutzfeld-Jacobs disease or viral encephalitis are commonly considered as differential diagnosis (4).

SREAT is a rare disorder with around 100 cases reported (5). Mean age of presentation is 44 years; however, it can be found both in pediatric (6) and geriatric populations. Female sex is predominantly affected (70-80% of patients) (7), an epidemiological fact that is in line with the autoimmune etiological hypothesis.

The first documented case dates from 1966 (8): Dr. Brain reported that a patient affected by Hashimoto thyroiditis with high titers of anti-thyroid antibodies presented subsequent episodes of encephalopathy and stroke-like symptoms.

As previously reported (9,10), diagnosis of SREAT should be suspected on the basis of clinical and laboratory findings as summarized in **Table 1**. Although they do not represent key diagnostic elements, the following features has been described in SREAT patients: (i) electroencephalogram (EEG) abnormalities (detected in up to 98% of patients), especially generalized slowing pattern (11); (ii) normal or unspecific findings in neuroimaging studies such as brain magnetic resonance imaging (12).

Thyroid status seems to have no relationship with the clinical presentation of encephalopathy: symptoms occur independent of thyroid function or underlying thyroid autoimmune disorder (13). Even if the most common associated thyroid disease is represented by Hashimoto hypothyroidism, SREAT can be observed also in patients with hyperthyroidism or euthyroid function (14). Consequently, the definition of such disease as “Hashimoto encephalopathy” does not seem to be fully accurate (15). Lacking a strong correlation with Hashimoto thyroiditis, it became common defining this clinical condition as SREAT or “nonvasculitic autoimmune meningoencephalitis” (16).

Although several hypothesis have been proposed, SREAT pathogenesis is still a matter of discussion. The

autoimmune etiology seems to be likely, taking into account female prevalence, association with autoimmune disorders, relapsing-remitting clinical course, and good response to corticosteroid treatment. Anti-thyroid antibodies might have a central pathogenic role; however, their titer does not correlate with disease severity and, notably, they are also detectable in healthy population (17). Moreover, anti-thyroid antibodies have been found in the cerebrospinal fluid (CSF) of SREAT patients. Thus, anti-thyroid antibodies detection in CSF has been proposed as a potential diagnostic marker (18).

Recently, abnormal levels of antibodies specific for alpha-enolase, an antigen expressed on central nervous system vessels and involved in autoimmune vasculitis (19), have been detected in SREAT patients suggesting its usefulness as a diagnostic marker of encephalopathy (20).

Uncertainties on etiology and pathogenesis match with lack of specific clinical presentation patterns. Symptoms are heterogeneous: cognitive impairments, consciousness disorders, hallucinations, headache, ataxia, coma, seizures and status epilepticus, myoclonus, visual deficits, and motor or sensory deficits (21). Moreover, acute onset of psychosis, depressive symptoms or mania as initial manifestations have also been reported (22,23).

In clinical practice it can be useful to distinguish SREAT patients into two different clinical groups: (i) patients who present a relapsing-remitting course, referred as vasculitic type or stroke-like type; (ii) patients with insidious onset and progressive course leading to cognitive dysfunction (24). Giving its variegated clinical presentation, SREAT still represents a hardly detectable nosographic entity. Thus, SREAT patients are often unrecognized and misdiagnosed with other neurological or psychiatric disorders.

From a psychiatric perspective, only few data have been published on the most adequate management of such patients. Symptom severity and rapid clinical remission after corticosteroid treatment underline the relevance of considering SREAT in the differential diagnosis process among patients with acute psychoneurological symptoms. In particular, this diagnostic hypothesis should be considered in psychiatric patients with a history of thyroid disorder.

We here report the case of a 19-year-old female SREAT patient, previously described by neurologist colleagues of our neuroscience department for her peculiar epileptic manifestations (25), focusing on neuropsychiatric symptomatology, its evaluation and subsequent appropriate management.

Table 1. Clinical and laboratory findings associated with SREAT diagnosis

<ul style="list-style-type: none"> • Clinical presentation of neuropsychological symptoms, mainly with relapsing-remitting episodes.
<ul style="list-style-type: none"> • No other detectable causes of encephalopathy (CSF negative for infectious disease, no neuroimaging signs for identifiable neurological disorders).
<ul style="list-style-type: none"> • Abnormal elevation of anti-thyroid antibody titers: predominantly anti-thyroid peroxidase antibody (anti-TPO Ab) but also anti-thyroglobulin (anti-TG Ab). Notably, the degree of titer elevation does not correlate with the severity of the clinical picture.
<ul style="list-style-type: none"> • CSF findings: elevated proteins; presence of thyroid antibodies (anti-TPO Ab and anti-TG Ab) with probably intrathecal production.
<ul style="list-style-type: none"> • Symptomatic improvement or remission after corticosteroid treatment.
CSF: cerebrospinal fluid.

CASE REPORT

C.A. is a young girl who was evaluated by our group in the emergency department for acute symptoms characterized by: subtotal insomnia, thought acceleration, formal thought disorder, social withdrawal, hyporexia and induction of vomiting. During psychiatric evaluation, the patient showed mild psycho-motor agitation and behavioral disinhibition, speech appeared fragmented and thought disorganized, delusional unstructured erotomanic content was present. The patient also showed great anxiety. Brain computed tomography was normal, and routine laboratory tests showed no alterations. Thus, she was admitted to the psychiatric ward for diagnostic and therapeutic evaluation. Anamnesis was positive for Basedow-Graves disease, which had been diagnosed when she was 7 years old; she had been treated with methimazole until the age of 15, when the patient spontaneously suspended the therapy. No previous relevant psychiatric episodes were reported.

During hospitalization the patient showed a severe thought disorganization, with derailment and tangentiality. No signs or symptoms of hallucination were present. Affect resulted fatuous, behavior appeared incongruous, and the mood was elevated. The Brief Psychiatric Rating Scale (BPRS) (26) was performed (total score=76), showing critical items such as elated mood, unusual thought content, bizarre behavior, conceptual disorganization, excitement, motor hyperactivity (**Figure 1**).

The first diagnostic hypothesis concerned mood disorder presenting with acute mania; thus, treatment with mood stabilizer, atypical antipsychotics and benzodiazepines was started. Moreover, considering the psychiatric symptoms exacerbation, especially the infantile erotomanic behavior, when the patient met her parents, another diagnosis that needed to be verified was the presence of conversion disorder.

In addition to routine laboratory tests, on the basis of anamnestic thyroid disease, specific organ autoimmunity was performed. Results are summarized in **Table 2**. Despite the presence of anti-thyroid antibodies, the patient showed normal blood concentrations of thyroid hormones. Thyroid ultrasonography was performed and showed an inhomogeneous echotexture of the thyroid gland with no solid nodules. The presence of anti-thyroid-stimulating hormone (TSH) receptor antibodies confirmed the diagnosis of Basedow-Graves disease.

Twelve days after admission, the initial improvement was followed by deterioration of the patient conditions, characterized by consciousness alterations. The patient appeared obtunded and only respondent to painful stimuli. We re-evaluated the BPRS and observed, as critical items, blunted affect, emotional withdrawal and motor retardation (**Figure 1**). Pharmacological treatment was then suspended. The neurological exam did not show any focal neurological signs, but was characterized by the presence of repetitive forceful yawning and swallowing movements. A video-EEG was performed showing a generalized slo-

wing pattern with yawning and swallowing related to partial, bilateral, asynchronous seizures with temporal outbreak (seizures receded after valproate treatment).

No previous epileptic manifestations were present in the patient's anamnesis, thus it seemed to be the onset of a new condition which had to be evaluated. Viral encephalitis, as likely etiology of the rapid deterioration of neurological condition, was supposed and empirical antiviral therapy was immediately started. A lumbar puncture was performed in order to elucidate whether we were facing an infectious case. However, CSF exam was normal. Consequently, the infectious hypothesis could be dismissed and antiviral therapy suspended.

Brain magnetic resonance imaging with and without contrast was performed to exclude acute intracranial process.

In accordance with neurology colleagues, the patient was admitted to the neurology ward to complete clinical research and start adequate treatment for epileptic manifestations. Once the epileptic state receded, the patient kept on showing psychiatric symptoms comparable to first manifestations, with elated mood and behavioral alteration, which still did not improve after psychiatric treatment.

According to current evidence (27-29), SREAT was supposed as a possible diagnosis, considering that any other acute process had been excluded and elevated titers of anti-thyroid antibodies were detected. Although encephalopathy is usually associated with Hashimoto thyroiditis, cases with positive anamnesis for Graves's disease have been reported.

A new CSF exam was performed to test the presence of anti-thyroid antibodies in our patient. CSF, with normal total protein concentrations, was positive for: (i) anti-TPO Ab 1040,85 IU/ml; (ii) anti-TG Ab 17,46 IU/ml. Moreover, normal albumin CSF/serum quotient (Qalb) was found, suggesting the integrity of the blood-brain barrier and the plausible intrathecal synthesis of the antibodies detected. Based on such findings, treatment with high-dose corticosteroids was started (methylprednisolone 1000 mg/day for 5 days). The patient gradually and completely recovered, with remission of psychiatric symptoms, thus SREAT diagnosis was confirmed.

At discharge, re-evaluation of BPRS demonstrated no critical items with a 34 total score point (**Figure 1**).

CONCLUSIONS

SREAT represents a rare clinical condition, which is likely to be under-diagnosed. It might remain unknown to many physicians for its heterogeneous clinical presentation. The reported case is paradigmatic as an example of how common psychiatric symptoms can hide an underlying SREAT. It represents a rare situation in which a psychiatric disorder can be successfully

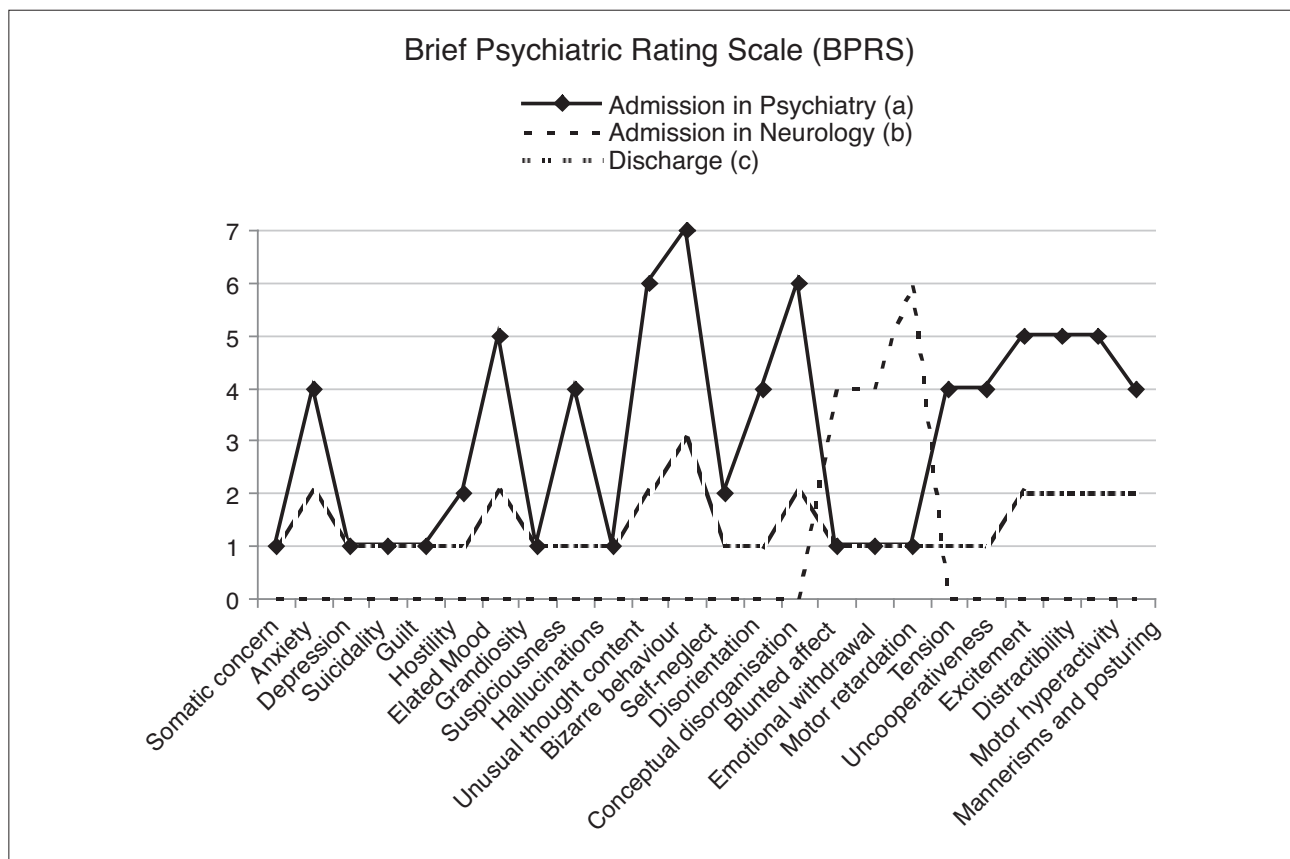


Figure 1. BPRS variations during clinical observation and after treatment. Each symptom is rated 1 to 7: 0, not evaluated; 1, absent; 2, very mild; 3, mild; 4, moderate; 5, moderately severe; 6, severe; 7, extremely severe.

Anti-thyroperoxidase (IU/ml)	600 [n.v. 0-34]
Anti-thyroglobulin (IU/ml)	212.20 [n.v. 0-115]
Anti-thyroid-stimulating hormone receptor (IU/l)	3.34 [n.v. <1.22]

treated with rapid and complete remission after drug administration. Consequently, it appears relevant for clinicians to know and consider this nosographic entity in the differential diagnostic algorithm, especially in those cases where the search for other causes has not led to an answer.

In our opinion, anti-thyroid antibody screening in patients with acute psychiatric onset and personal history of autoimmune thyroid disease might be useful as a diagnostic tool. Further studies are needed to elucidate and better understand this uncommon but treatable condition.

REFERENCES

1. Mocellin R, Walterfang M, Velakoulis D. Hashimoto’s encephalopathy: epidemiology, pathogenesis and management. *CNS Drugs* 2007; 21: 799-811.
2. Marshall GA, Doyle JJ. Long-term treatment of Hashimoto’s encephalopathy. *J Neuropsychiatry Clin Neurosci* 2006; 18: 14-20.
3. Boers PM, Colebatch JG. Hashimoto’s encephalopathy responding to plasmapheresis. *J Neurol Neurosurg Psychiatry* 2001; 70: 132.
4. Santoro D, Colombo I, Ghione I, et al. Steroid-responsive Hashimoto encephalopathy mimicking Creutzfeldt-Jakob disease. *Neurol Sci* 2011; 32: 719-22.
5. Lee SW, Donlon S, Caplan JP. Steroid responsive encephalopathy associated with autoimmune thyroiditis (SREAT) or Hashimoto’s encephalopathy: a case and review. *Psychosomatics* 2011; 52: 99-108.
6. Alink J, de Vries TW. Unexplained seizures, confusion or hallucinations: think Hashimoto encephalopathy. *Acta Paediatr* 2008; 97: 451-3.
7. Kothbauer-Margreiter I, Sturzenegger M, Komor J, Baumgartner R, Hess CW. Encephalopathy associated with Hashimoto thyroiditis: diagnosis and treatment. *J Neurol* 1996; 243: 585-93.

Acute psychiatric presentation of steroid-responsive encephalopathy

8. Brain L, Jellinek EH, Ball K. Hashimoto's disease and encephalopathy. *Lancet* 1966; 2: 512-4.
9. Chong JY, Rowland LP, Utiger RD. Hashimoto encephalopathy: syndrome or myth? *Arch Neurol* 2003; 60: 164-71.
10. Ferracci F, Moretto G, Candeago RM, et al. Antithyroid antibodies in the CSF: their role in the pathogenesis of Hashimoto's encephalopathy. *Neurology* 2003; 60: 712-14.
11. Schauble B, Castillo PR, Boeve BF, Westmoreland BF. EEG findings in steroid-responsive encephalopathy associated with autoimmune thyroiditis. *Clin Neurophysiol* 2003; 114: 32-7.
12. Song YM, Seo DW, Chang GY. MR findings in Hashimoto encephalopathy. *AJNR Am J Neuroradiol* 2004; 25: 807-8.
13. Sawka AM, Fatourehchi V, Boeve BF, Mokri B. Rarity of encephalopathy associated with autoimmune thyroiditis: a case series from Mayo Clinic from 1950 to 1996. *Thyroid* 2002; 12: 393-8.
14. Payer J, Petrovic T, Baqui L, Lisy L, Langer P. Hashimoto's encephalopathy and rare cases of hyperthyroidism (review and case report). *Endocr Regul* 2009; 43: 169-78.
15. Cantón A, de Fàbregas O, Tintoré M, Mesa J, Codina A, Simó R. Encephalopathy associated to autoimmune thyroid disease: a more appropriate term for an underestimated condition? *J Neurol Sci* 2000; 176: 65-9.
16. Chong JY, Rowland LP. What's in a NAIM? Hashimoto encephalopathy, steroid-responsive encephalopathy associated with autoimmune thyroiditis, or nonvasculitic autoimmune meningoencephalitis? *Arch Neurol* 2006; 63: 175-6.
17. Hollowell JG, Staehling NW, Flanders WD, et al. Serum TSH, T4, and thyroid antibodies in the United States population (1988 to 1994): National Health and Nutrition Examination Survey (NHANES III). *J Clin Endocrinol Metab* 2002; 87: 489-99.
18. Ferracci F, Bertiato, G, Moretto G. Hashimoto's encephalopathy: epidemiologic data and pathogenetic considerations. *J Neurol Sci* 2004; 217: 165-8.
19. Ochi H, Horiuchi I, Araki N, et al. Proteomic analysis of human brain identifies alpha-enolase as a novel autoantigen in Hashimoto's encephalopathy. *FEBS Lett* 2002; 528: 197-202.
20. Fujii A, Yoneda M, Ito T, et al. Autoantibodies against the amino terminal of alpha-enolase are a useful diagnostic marker of Hashimoto's encephalopathy. *J Neuroimmunol* 2005; 162: 130-6.
21. Castillo P, Woodruff B, Caselli R, et al. Steroid-responsive encephalopathy associated with autoimmune thyroiditis. *Arch Neurol* 2006; 63: 197-202.
22. Wilcox RA, To T, Koukourou A, Frasca J. Hashimoto's encephalopathy masquerading as acute psychosis. *J Clin Neurosci* 2008; 15: 1301-4.
23. Arrojo M, Perez-Rodriguez MM, Mota M, et al. Psychiatric presentation of Hashimoto's encephalopathy. *Psychosom Med* 2007; 69: 200-1.
24. Schiess N, Pardo CA. Hashimoto's encephalopathy. *Ann N Y Acad Sci* 2008; 1142: 254-65.
25. Casciato S, Di Bonaventura C, Lapenta L, et al. Recurrent partial seizures with ictal yawning as atypical presentation of Hashimoto's encephalopathy (steroid-responsive encephalopathy associated with autoimmune thyroiditis). *Epilepsy Behav* 2011; 22: 799-803.
26. Overall JE, Gorham DR. The brief psychiatric rating scale. *Psychological Reports* 1962; 10: 799-812.
27. Tamagno G, Celik Y, Simó R, et al. Encephalopathy associated with autoimmune thyroid disease in patients with Graves' disease: clinical manifestations, follow-up, and outcomes. *BMC Neurol* 2010; 10: 27.
28. Ngiu CS, Ibrahim NM, Yahya WN, et al. A case of Hashimoto encephalopathy in a Malay woman with Graves disease. *BMJ Case Rep* 2009; 2009: bcr01.2009.1501.
29. Saito H, Fujita N, Miyakoshi M, Arai A, Nagai H. A case of Hashimoto's encephalopathy associated with Graves' disease. *Rinsho Shinkeigaku* 2002; 42: 619-22.