

Caso clinico

Hormonal imbalance and pituitary adenoma during antipsychotic treatment in an adolescent with bipolar affective disorder

Squilibrio ormonale e adenoma pituitario durante il trattamento antipsicotico in un adolescente con disturbo affettivo bipolare

FLORINA RAD¹, ALEXANDRA MARIANA BUICA^{1*}, GIANINA CRISTINA ANGHEL¹,
MIHAELA STANCU¹, IULIANA DOBRESCU¹

*E-mail: alexa_de_du@yahoo.com

¹Child and Adolescent Psychiatry Department, University of Medicine and Pharmacy "Carol Davila", Bucharest, Romania

SUMMARY. In this paper we present the case of a female teenager patient who was diagnosed with bipolar affective disorder and during psychotropic treatment with risperidone, the prolactin levels ranged between 55 ng/mL and 85 ng/mL at monthly repeated dosing. During this period, the patient presented somatic alterations in her state of health. The patient benefited from brain imaging, which revealed that in *sella turcica* is distinguished a well-defined and relatively homogeneous formation, measuring approximately 11/8 mm, suggestive of a pituitary adenoma. After changing the antipsychotic treatment, the pituitary formation resolved to a subsequent imaging re-evaluation.

KEY WORDS: antipsychotics, pituitary adenoma, prolactin, adolescents.

RIASSUNTO. In questo articolo presentiamo il caso di una paziente adolescente a cui era stato diagnosticato un disturbo affettivo bipolare; durante il trattamento psicotropico con risperidone, i livelli di prolattina variavano da 55 ng/mL a 85 ng/mL con dosaggio mensile ripetuto. Durante questo periodo, la paziente presentava alterazioni somatiche. Ha tratto vantaggio dall'imaging cerebrale, che ha rivelato che nella sella turcica si distingue una formazione ben definita e relativamente omogenea, che misura circa 11/8 mm, che suggerisce un adenoma pituitario. Dopo aver modificato il trattamento antipsicotico, la formazione pituitaria si è risolta in una successiva rivalutazione di imaging.

PAROLE CHIAVE: antipsicotici, adenoma pituitario, prolattina, adolescenti.

INTRODUCTION

Atypical antipsychotics often increase prolactin hormone, and as a result, the morphology of the gland also changes¹. Antipsychotic medication therapy, which in many cases must be administered over a very long period of patient's life, remains the basic approach for treating a large area of psychiatric pathologies. As the most recent state of the art concludes, atypical antipsychotics interacts with central and peripheral neurotransmitter systems and with different hormonal production².

The appearance of pituitary tumors during treatment with risperidone was reported in many recent scientific publications. Because such tumors are highly prevalent, there may be other reasons why they were revealed in association with risperidone treatment. One of this explanations could be the fact that psychotic patients with risperidone treatment are more often assessed with brain imaging³.

Our particular interest in thorough documenting the influence of atypical antipsychotics on the activity of the pituitary gland, added to the recent literature information that is summarized above, come in support of the case of a female teenag-

er patient who was evaluated by our team, and that we want to expose in the light of these particularities. At her first admission in our department, the patient already had a personal pathological history of psychiatric disorder, and for the last two years she was monitored in terms of mental state and psychotropic treatment in Neuropsychiatry service from territory.

CASE PRESENTATION

Her first admission in a Child and Adolescent Psychiatry Service was at the age of 13, in 2014, for severe insomnia, sadness, anxiety, psychomotor slowing, thought blocking, anhedonia, delusions of persecution, disorganized behavior. The symptomatology had installed suddenly, for about five days previous admission, persisting with mild periodic spontaneous improvement. At this first evaluation the patient was diagnosed with acute psychotic disorder, and was discharged with therapeutic recommendation consisting of a benzodiazepine (treatment with lorazepam for two weeks, with gradually reduction of doses) and risperidone 2.25 mg/day divided into two doses.

Rad F et al.

After two months of treatment, the patient is presenting for reevaluation, showing persistent symptoms of psychomotor agitation, anxiety, severe insomnia, difficulties in adapting in the community, emotional lability, delusions of persecution, hypochondriacally concerns. At this point it was investigated the sanguine level of prolactin, and the results revealed a plasmatic level of prolactin of 63.2 ng/mL (general guidelines for diagnosing prolactin excess (hyperprolactinemia) define the upper threshold of normal prolactin at 25 ng/mL for women and 20 ng/mL for men)⁴. The patient continued the psychopharmacological treatment with risperidone. All medical information exhibited so far have been provided by the family, all medical decisions related to the psychiatric treatment belonged to the team of specialists from the territory who managed the case until presenting in our clinic.

In the coming months, patient's symptomatology has improved (she no longer experienced mood changes, psychotic elements or delusions), only the social anxiety was still maintained. Although risperidone doses were adjusted at 1 mg/day, the prolactin levels ranged between 55 ng/mL and 85 ng/mL at monthly repeated dosing.

During this period the patient presented somatic alterations in her state of health: galactorrhea, breast enlargement, menstrual cycle dysfunction, weight gain of about 5 kg (at her first admission she weighed 51 kg, after six months she gained 5 kg).

At this point in the evolution of psychiatric symptomatology, corroborated with somatic complaints and modified hormonal blood parameters, the family decided the reassessment of the patient in Child and Adolescent Department from "Alexandru Obregia" Hospital. When she presented to our clinic, the team decided to evaluate the pituitary's morphology. Also from the necessity of excluding any cerebral expansive process that could explain this symptomatology with sudden onset at a very early age, our patient benefited from brain imaging. After 10 months of treatment with risperidone, the patient had a brain MRI, which revealed

that in sella turcica is distinguished a well-defined and relatively homogeneous formation, measuring approximately 11/8 mm, suggestive of a pituitary adenoma (Figure 1). Following neurosurgical evaluation, it was postponed surgical ablation of this formation, following that its morphology to be monitored according to psychotropic received medication and hormonal dosage that patient will repeat.

Following the decision of the multidisciplinary team that managed the evolution of the previous presented case (neurosurgeon, endocrinologist, gynecologist, child and adolescent psychiatrist), the patient discontinued psychotropic medication for a period of two months. After about one month after discontinuation of risperidone, prolactin values have returned to normal, and somatic symptoms experienced considerable improvement. After approximately two months without any psychotropic medication, the patient was admitted in territory's service of child and adolescent psychiatry for feeling excessively happy, experiencing increased talkativeness, increased confidence and self-esteem, increased social activity with decreased inhibitions, all suggestive for a mania episode. The patient was discharged with a diagnosis of bipolar affective disorder and the treatment consisted of a typical antipsychotic medication (haloperidol) and a mood stabilizer.

Under this treatment, symptomatology veered to the other pole of effectiveness, presenting symptoms for a depressive episode, and the patient accompanied by her parents is addressing to our clinic for clinical and therapeutically reassessment.

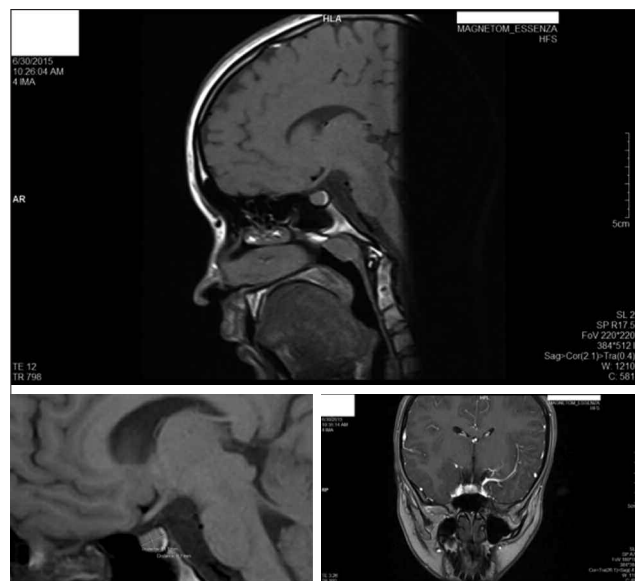


Figure 1. Brain MRI after 10 months of antipsychotic treatment.

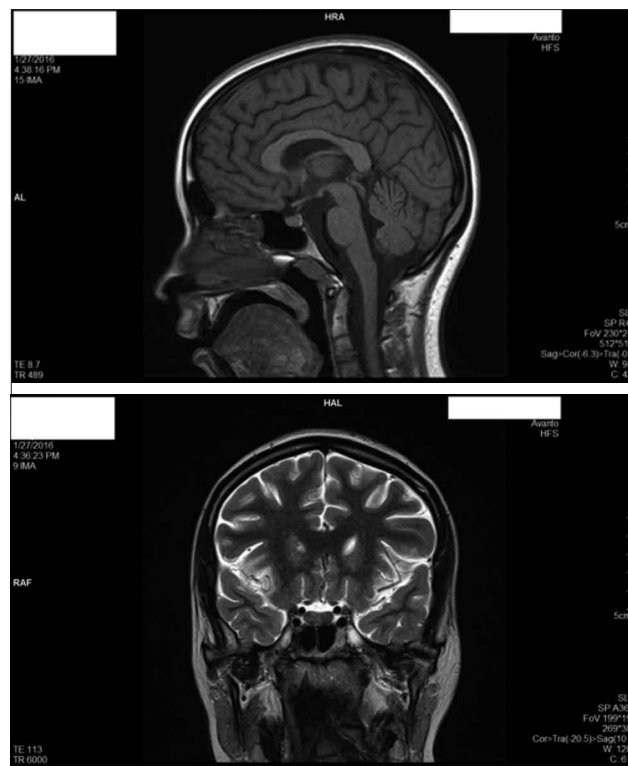


Figure 2. Brain MRI after 4 months of risperidone discontinuation.

Hormonal imbalance and pituitary adenoma during antipsychotic treatment in an adolescent with bipolar affective disorder

During this hospitalization, the patient received treatment with atypical antipsychotic (olanzapine) and tricyclic antidepressant (clomipramine). Also it was repeated brain imaging and prolactin levels. So far, prolactin serum level was not higher than 17 ng/mL during treatment with olanzapine. Brain MRI revealed a pituitary gland with structure and thickness within normal limits, without objectifying adenoma (Figure 2). The patient currently receives 2.5 mg/day of olanzapine, and prolactin values, dosed every 2 weeks, are within normal limits. Affective symptoms are currently in remission.

CONCLUSIONS

By exposing this case report, we wanted to bring into focus the importance of a multidisciplinary team in the difficult management of this mental disorder. The challenging treatment approach required taking into account the fact that many therapeutic factors that we use in psychiatric practice can precipitate endocrine pathology that the patient has confronted with.

The overall conclusion of this presentation suggests that prolactin levels may normalize in patients with mental disorders, and the return to normal prolactinemia may offer patients improvements in comorbid symptoms of reproductive dysfunctions and even the normalization of pituitary volume.

Conflict of interests: the authors have no conflict of interests to declare.

REFERENCES

1. Sam S, Frohman LA. Normal physiology of hypothalamic pituitary regulation. *Endocrinol Metab Clin North Am* 2008; 37: 1-22.
2. Szarfman A, Tonning JM, Levine JG, Doraiswamy PM. Atypical antipsychotics and pituitary tumors: a pharmacovigilance study. *Pharmacotherapy* 2006; 26: 748-58.
3. Upadhyaya AR, El-Sheikh R, MacMaster FP, Diwadkar VA, Keshavan MS. Pituitary volume in neuroleptic-naive schizophrenia: a structural MRI study. *Schizophr Res* 2007; 90: 266-73.
4. Mancini T, Casanueva FF, Giustina A. Hyperprolactinemia and prolactinomas. *Endocrinol Metab Clin North Am* 2008; 37: 67-99.