

Casi clinici

Postoperative heroin-withdrawal delirium treated with clonazepam after urgent cardiac surgery: a case report

Delirio post-operatorio da astinenza da eroina trattato con clonazepam dopo chirurgia cardiaca urgente: un caso clinico

RAFFAELE GAETANO^{1#}, RENATO DE FILIPPIS^{1*#}, MARIARITA CAROLEO¹, CRISTINA SEGURA-GARCIA², PASQUALE DE FAZIO¹

*E-mail: defilippisrenato@gmail.com

[#]These authors contributed equally to this work

¹Department of Health Sciences, University Magna Graecia of Catanzaro, Italy

²Department of Medical and Surgical Sciences, University Magna Graecia of Catanzaro, Italy

SUMMARY. Postoperative delirium (POD) is a complication that can occur in patients of any age undergoing major surgery. Due to the high incidence of delirium morbidity and mortality, it is important to identify and treat delirium quickly and successfully. Although many organic, surgical and psychiatric risk factors are recognized as putative causes of delirium, heroin withdrawal is not yet well defined and evaluated in the prevention and treatment of POD. We report a case report of a multi-drug addicted patient, without any other psychiatric comorbidity, suffering from heroin-withdrawal POD after urgent major cardiac surgery, successfully treated with clonazepam orally after conventional therapy failure. At the time of discharge, POD was completely solved and without further complications, psychiatric therapy was further reduced just to a low dose of clonazepam and the patient was referred to a specialized drug abuse center. The reported case suggests that clonazepam may be considered a valid option in case of heroin-withdrawal POD after conventional treatments failure.

KEY WORDS: postoperative delirium, heroin withdrawal; clonazepam; major cardiac surgery; case report.

RIASSUNTO. Il delirium post-operatorio è una complicanza post-chirurgica che può verificarsi in pazienti di ogni età che si sottopongono a interventi di chirurgia maggiore. Vista l'alta incidenza di morbilità e mortalità associate al delirium, risulta essere importante identificare e trattare il delirium rapidamente e adeguatamente. Sebbene vi siano molti fattori di rischio organici, chirurgici e psichiatrici riconosciuti come possibili cause di delirium, l'astinenza da eroina non è ancora stata annoverata e valutata tra queste nella prevenzione e nel trattamento del delirium post-operatorio. Riportiamo un caso clinico di un paziente con pluridipendenza da sostanze, senza alcuna altra comorbilità psichiatrica, affetto da delirium post-operatorio da astinenza da eroina dopo intervento cardiocirurgico urgente, trattato con successo con clonazepam orale successivamente a fallimento del trattamento convenzionale. Al momento della dimissione, il delirium post-operatorio si era completamente risolto senza alcuna sequela, la terapia psichiatrica è stata limitata solo a una bassa dose di clonazepam e il paziente è stato indirizzato a una clinica specializzata nel trattamento delle dipendenze da sostanze. Il caso riportato suggerisce come il clonazepam possa essere considerato una opzione in caso di delirium post-operatorio da sospensione di eroina dopo il fallimento dei trattamenti convenzionali.

PAROLE CHIAVE: delirium post-operatorio, astinenza da eroina, clonazepam, chirurgia maggiore cardiaca.

INTRODUCTION

Delirium is characterized by fluctuation of consciousness affecting attention, awareness, and cognition, as defined by the Diagnostic and Statistical Manual 5th edition (DSM-5) or by the 10th revision of the International Statistical Classification of Diseases and Related Health Problems (ICD-10).

Postoperative delirium (POD) is a complication that can occur in patients of any age undergoing major surgery. The incidence varies according to age, and it is substantially influenced by patient-related risk factors (e.g. age, comorbidity) and type of surgery. Major surgery and emergency surgery are precipitating risk factors of POD indeed.

Elderly are at higher risk for cognitive impairment, comorbid medical conditions, dehydration, malnutrition, im-

paired functional status and frailty¹. Thus, comorbid multi-organ dysfunction before surgery, low hemoglobin concentration, low ejection fraction, carotid artery stenosis or high serum creatinine concentration increase the incidence of POD². On the other hand, POD is associated with several negative clinical consequences, including major postoperative complications, reduced functional outcomes, cognitive decline, lesions of surgical wounds, increased duration of hospital stay with higher costs and higher mortality³⁻⁵.

Cardiac surgery is associated with a high risk either for delirium and the development of long term brain dysfunctions⁶. Higher mortality rates, hospital-acquired complications, persistent cognitive impairments, poor functional recovery following surgery and increased healthcare costs are common consequences of delirium⁷.

Opioid receptors are widely present in the central nerv-

ous system (CNS)⁸; CNS side effects related to opium abuse include drowsiness, dizziness, restlessness, headache, malaise, CNS depression, insomnia, and mental depression⁹. Some evidence correlated delirium with opium abuse^{10,11}; opium addiction has been identified as a possible risk factor for post-operative delirium after cardiac surgery¹². However, there are not robust literature data on the management of POD in opioid abusers or withdrawal.

We report the case of a multi-drug addicted patient, without any other psychiatric comorbidity, suffering from heroin-withdrawal POD after urgent major cardiac surgery, successfully treated with oral clonazepam after conventional therapy failure. We reported this clinical case following the CARE (CAse REport) Statement and Checklist¹³. The case report timeline is summarized in Figure 1.

REASON FOR THE REPORT

To the best of our knowledge this represents the first reported clinical case of a delirium positively treated with clonazepam after a poor clinical response to the first- and second-line pharmacological treatment according to current international guidelines. Furthermore, it deals with the treatment of a borderline situation with the combination of urgent cardiac surgery, heroin withdrawal and POD.

For this reason, in the context of the increasingly complex management of the drug-abuser patients, this case could be worthy of sharing with colleagues from different disciplines.

CASE PRESENTATION

A 37-old-man with a history of drug addiction (i.e. cocaine, heroin, cannabis), without neither any other previous psychiatric conditions nor alcohol abuse/dependence, is admitted at the emergency room for a Stanford type-A aorta dissection and cardiogenic shock, after 36 hours of general malaise. He appeared sore, restless and worried, was lucid and oriented but could not stand on his legs and screamed in pain, with a Glasgow Coma Scale (GCS) score of 14. No history of neurological disease, head injury, or seizures was reported.

An abdominal thoracic angio-CT confirmed the presence of an aortic dissection from the valvular plane up to the aortic arch, involving the left subclavian artery of the brachiocephalic trunk up to both carotid arteries, with minimum pericardial effusion.

The patient underwent emergency surgery to replace the ascending aorta with a tube graft; then he was transported in intensive care for the normal postoperative stay and surgical wound management. The day after, the onset of hyperpyrexia and a positive blood culture for *Escherichia Coli* on central venous catheter, makes it necessary the infectious disease specialist consultation. The catheter was removed, and a specific antibiotic therapy with ceftazidime and clindamycin was started. The response to antibiotic therapy was complete and no other symptoms of infections leading to suspecting a septic shock were observed.

Approximately 36 hours after the surgery, following seda-

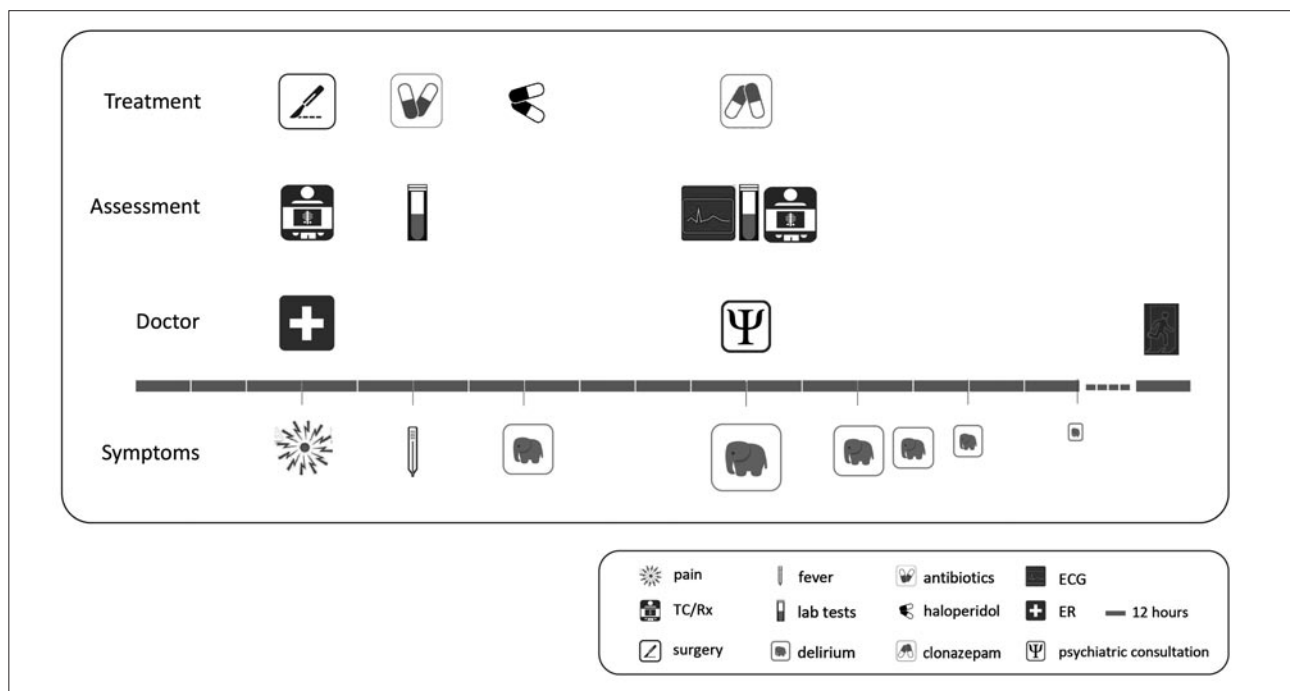


Figure 1. Case report clinical timeline.

Delirium treated with clonazepam

Table 1. Lab tests at the time of psychiatric consultation.

Investigation	Patient observed value	Unit	Lab normal range
Sodium	146	mmol/L	137-147
Potassium	3.6	mmol/L	3.5-4.5
Chlorine	112	mmol/L	98-106
Magnesium	2.1	mg/dL	1.58-2.3
Calcium	8.6	mg/dL	8.4-10.2
CK-MB	8.5	ng/mL	<4.94
CK-MM	380	IU/L	35-310
Myoglobin	390	ng/mL	25-72
hs-cTnT	0.119	ng/mL	<0.014
AST	154	IU/L	<38
ALT	125	IU/L	<41
LDH	800	IU/L	240-480
GGT	115	IU/L	8-61
Glycemia	75	mg/dL	70-110
Iron	18	mcg/dL	61-157
Lipase	87	IU/L	13-60
Amylase	68	IU/L	28-100
Creatinine	0.57	mg/dL	0.70-1.20
Urea	63	mg/dL	10-50
Total bilirubin	0.28	mg/dL	< 1.10
Direct bilirubin	0.16	mg/dL	< 0.30
Indirect bilirubin	0.12	mg/dL	< 1.10

ALT= Alanine aminotransferase; AST= Aspartate aminotransferase; CK-MB= Creatine Kinase-Myocardial Band; CK-MM= Creatine Kinase muscle; hs-cTnT= High-Sensitivity Cardiac Troponin T; LDH= lactate dehydrogenase; GGT= Gamma-Glutamyl Transferase.

tive therapy suspensions, the patient exhibited an abrupt behavioral and mood change; he showed psychomotor agitation, hyper-reactivity to tactile and auditory stimuli, dysregulation of the sleep-wake cycle and vital signs destabilization. Moreover, visual and auditory hallucinations, in a state of confusion and altered consciousness were evident. A clinical diagnosis of delirium was then made. In the next two days, attempts to manage the psychomotor agitation with of haloperidol (5 mg im/day), lorazepam (4 mg im x 3/day) and midazolam (5 mg ii/day) were unsuccessful, so a psychiatric counseling was requested.

During the psychiatric visit, the patient appeared confused, agitated, disoriented in time and space, almost violent, with a GCS score of 10. Additionally, he had lacrimation, rhinorrhea, diarrhea, insomnia and mydriasis. Evaluations, including vital parameters, liver function tests, serum electrolytes, blood glucose levels, kidney-function tests, urinalysis, ammonia, muscle enzymes, creatinine and blood gas analysis, electrocardiogram and chest X-ray did not justify a clinical presentation of POD with the consequent high risk of the patient tearing the sutures (Tables 1-2).

Table 2. Venous blood gas analysis at the time of the psychiatric consultation.

Investigation	Patient observed value	Unit	Lab normal range
pH	7.45	NA	7.35-7.45
pCO ₂	37	mmHg	35-45
pO ₂	32	mmHg	30-40
Na ⁺	145	mmol/L	136-145
K ⁺	3.2	mmol/L	3.5-5
Ca ⁺⁺	0.98	mmol/L	1.1-1.4
Glycemia	95	mg/dL	70-100
Lactate	0.8	mmol/L	0.5-2
Hct	24	%	35-45
HCO ₃ ⁻	25.7	mmol/L	21-28
TCO ₂	26.8	mmol/L	21-30
Base excess	1.7	mmol/L	(-2)-(+2)
SO ₂ c	65	%	65-75
THbc	7.4	g/dL	13-17

Ca⁺⁺= calcium; HCO₃⁻= Concentration of hydrogen carbonate; Hct= Hematocrit; K⁺= potassium; NA= not applicable; Na⁺= sodium; pCO₂= Carbon dioxide partial tension; pO₂= oxygen tension; SO₂c= calculated oxygen saturation; TCO₂= total carbon dioxide; THbc= total calculated hemoglobin.

Drug testing detected higher rates of cannabinoids, benzodiazepines and barbiturates (Table 3), probably also due to the previous sedative therapy. Borderline results for amphetamines, cocaine and opiates and negative for alcohol and methadone were detected in a framework compatible with heroin abstinence. Consumption of heroin was later confirmed by the patient's parents and sister.

In light of the poor response to previous treatments and given the clinical condition, a therapy with clonazepam (3 mg x 3/day) was started. The first 3mg were administered during the consultation, and nearly 15 minutes later a slight reduction in muscle contractions of the limbs and reduced heart and respiratory rate were recorded. Therefore, clonazepam therapy was continued and other sedatives and antipsychotics were discontinued.

Some visual hallucinations, although criticized by the patient, were still present at the beginning of treatment, and even if disoriented, it was possible to talk with him maintaining direct eye contact. The day after, the patient appeared drowsy, clouded (GCS score 8) and difficult to wake up even with pain (i.e. pinching on the nipples) or auditory stimuli (i.e. calling him by name), but still preserving flexion withdrawal from pain.

The clinical improvement continued in the following days. The first aspect to improve was muscle spasms, followed by psychomotor agitation and spatial and temporal disorientation. The patient also began to remember and accurately de-

Table 3. Patient's drug-test.

Drug	Result	Urinary concentration	unit	Cut-off	LOQ
Amphetamines	borderline	412	ng/mL	<500	up to 2000
Barbiturates	positive	494.5	ng/mL	<300	up to 1000
Benzodiazepines	positive	>1000	ng/mL	<300	up to 1000
Cannabinoids	positive	69	ng/mL	<50	up to 100
Cocaine	borderline	185	ng/mL	<300	up to 1000
Opiates	borderline	256	ng/mL	<300	up to 1000
Buprenorphine	negative	1.7	ng/mL	<5	up to 100
Methadone	negative	<10	ng/mL	<50	up to 100
Alcohol	negative	0.3	gr/L	<0.5	up to 6

LOQ= limit of quantification.

scribe the days prior to admission and even his arrival at the hospital, while maintaining confused and circumstantial memories of the days after the surgery. The sleep-wake rhythm normalized only after 5 days. The patient also admitted the use of substances in the days prior to admission.

Given the clinical response and the positive medical history for drug abuse, clonazepam was reduced, first to 20 drops and then to 15 drops three times a day.

In the coming days an improvement in the clinical picture was observed: the patient had normal cardiac and respiratory rates, body temperature of 36.8 °C and no signs of systemic infection. For this reason, at the 10th day after surgery the patient was transferred to an intermediate residency for a better surgical wound management.

OUTCOME

At the time of discharge, POD was completely solved without any complication, psychiatric therapy with clonazepam was reduced to 12 drops twice a day and the patient was referred to drug abuse center.

DISCUSSION

We reported a clinical case report of a 37-years-old multi-drug addicted male patient, without any other psychiatric comorbidity, suffering from heroin-withdrawal POD after urgent major cardiac surgery, successfully treated with oral clonazepam after conventional therapy failure. However, although the patient had symptoms and signs referable to opi-

oid withdrawal, such as lacrimation, rhinorrhea, diarrhea, insomnia and mydriasis, the delirium has been started late. This may be due to the inference of general anesthesia undergone by the patient, which may have delayed the clinical manifestation of abstinence¹⁴. Other potential diagnosis, such as alcohol withdrawal, neuroleptic malignant syndrome, malignant hyperthermia, have been ruled out based on anamnestic, clinical and laboratory data. Although drug addiction and substance abstinence are not well codified situations and specific guidelines lack¹⁵, this case report shows that there may be borderline conditions in emergency or in unusual settings, not responsive to common treatments. Type-A Aortic Dissection Surgery with post-operative hospitalization and in general major surgery represented an important risk factor for the development of POD^{16,17}.

Clonazepam has been shown to be effective in the treatment of drug addiction and substance abstinence (i.e. opioids)¹⁸ and has also appeared to be effective in the treatment of heroin abstinence in this aforementioned multi drugs addicted patient after urgent cardiac surgery. This could be explained by the pharmacokinetic (e.g. long half-life) and pharmacodynamic (activation of the benzodiazepine-GABA receptor complex, serotonergic effects) characteristics of clonazepam, which make it a particularly suitable drug to treat withdrawal syndromes¹⁹.

Generally, opioids withdrawal is considered not relevant and the reports of serious withdrawal symptoms have been very few²⁰. However, sudden abstinence from opioids and aorta dissection resulting in surgery may have been a risk factor for delirium in our case.

Even though there is no scientific evidence, it could be inferred that, after an accurate differential diagnosis of other possible causes of POD, clonazepam may be useful to manage the withdrawal syndrome. However, in the presented case, it is difficult to differentiate between POD and the clinical manifestation of withdrawal syndrome. Therefore, studies with larger sample size are required to determine the prevalence and the cause of delirium after opioid withdrawal in surgical settings and to identify the best therapeutic management.

CONCLUSIONS

In this case report, no organic causes of delirium have been found and conventional treatments were not successful. Clinical history of substance abuse and positive drug testing led to the diagnosis of postoperative heroin-withdrawal delirium. The patient developed delirium after the acute suspension of heroin on waking up from major surgery. Moreover, the patient improved only after starting therapy with oral clonazepam.

Conflict of interests: the authors have no conflict of interests to declare.

Funding: we certify that we did not get any source of funding for the case report presented in the article being submitted.

REFERENCES

1. Bell SP, Patel N, Patel N, Sonani R, Badheka A, Forman DE. Care of older adults. *J Geriatr Cardiol* 2016; 13: 1-7.

Delirium treated with clonazepam

2. Aldecoa C, Bettelli G, Bilotta F, et al. European Society of Anaesthesiology evidence-based and consensus-based guideline on postoperative delirium. *Eur J Anaesthesiol* 2017; 34: 192-214.
3. Witlox J, Eurelings LSM, de Jonghe JFM, Kalisvaart KJ, Eikelenboom P, van Gool WA. Delirium in elderly patients and the risk of postdischarge mortality, institutionalization, and dementia: a meta-analysis. *JAMA* 2010; 304: 443-51.
4. Krzych LJ, Wybraniec MT, Krupka-Matuszczyk I, et al. Detailed insight into the impact of postoperative neuropsychiatric complications on mortality in a cohort of cardiac surgery subjects: a 23,000-patient-year analysis. *J Cardiothorac Vasc Anesth* 2014; 28: 448-57.
5. Bickel H, Gradingner R, Kochs E, Förstl H. High risk of cognitive and functional decline after postoperative delirium. *Dement Geriatr Cogn Disord* 2008; 26: 26-31.
6. Winter A, Steurer M, Dullenkopf A. Postoperative delirium assessed by post anesthesia care unit staff utilizing the Nursing Delirium Screening Scale: a prospective observational study of 1000 patients in a single Swiss institution. *BMC Anesthesiol* 2015; 15: 184.
7. Martocchia A, Curto M, Comite F, et al. The prevention and treatment of delirium in elderly patients following hip fracture surgery. *Recent Pat CNS Drug Discov* 2015; 10: 55-64.
8. Slamberová R. [Opioid receptors of the CNS: function, structure and distribution]. *Ceskoslov Fysiol [Internet]*. 2004 [cited 2019 Mar 24]; 53: 159-66.
9. Mokhlesi B, Leikin JB, Murray P, Corbridge TC. Adult toxicology in critical care: Part II: specific poisonings. *Chest* 2003; 123: 897-922.
10. Conde López VJ, Plaza Nieto JF, Macias Fernández JA, Losmos Sánchez JA. [Historical study of seven cases of delirium tremens in Spain in the first half of the XIX century]. *Actas Luso Esp Neurol Psiquiatr Cienc Afines* 1995; 23: 200-16.
11. Yoshimoto T, Hisada A, Hasegawa T, Nozaki Y, Matoba M; Symptom Control Research Group SCORE-G. [Efficacy and safety of continuous subcutaneous injection of the compound oxycodone in cancer pain management: the first 4-year audit]. *Gan To Kagaku Ryoho* 2009; 36: 1683-9.
12. Eizadi-Mood N, Aghadavoudi O, Najarzadegan MR, Fard MM. Prevalence of delirium in opium users after coronary artery bypass graft surgery. *Int J Prev Med* 2014; 5: 900-6.
13. Riley DS, Barber MS, Kienle GS, et al. CARE guidelines for case reports: explanation and elaboration document. *J Clin Epidemiol* 2017; 89: 218-35.
14. Brown EN, Pavone KJ, Naranjo M. Multimodal general anesthesia: theory and practice. *Anesth Analg* 2018; 127: 1246-58.
15. Reed K, Day E, Keen J, Strang J. Pharmacological treatments for drug misuse and dependence. *Expert Opin Pharmacother* 2015; 16: 325-33.
16. Hamilton GM, Wheeler K, Di Michele J, Lalu MM, McIsaac DI. A systematic review and meta-analysis examining the impact of incident postoperative delirium on mortality. *Anesthesiology* 2017; 127: 78-88.
17. Liu Z, Pang X, Zhang X, Cao G, Fang C, Wu S. Incidence and risk factors of delirium in patients after type-a aortic dissection surgery. *J Cardiothorac Vasc Anesth* 2017; 31: 1996-9.
18. Sharma RC, Kumar R, Sharma DD, Kanwar P. Opium withdrawal delirium: two case reports. *Psychopharmacol Bull* 2017; 47: 48-51.
19. Nardi AE, Perna G. Clonazepam in the treatment of psychiatric disorders: an update. *Int Clin Psychopharmacol* 2006; 21: 131-42.
20. Aggarwal A, Choudhary S, Jiloha RC. Opioid withdrawal delirium. *J Neuropsychiatry Clin Neurosci* 2011; 23: E37.