

## **Buprenorphine/naloxone (Suboxone®) withdrawal may facilitate antipsychotic-induced priapism. A case report**

**TOMMASO B. JANNINI<sup>1</sup>, GIORGIO DI LORENZO<sup>1,2</sup>, ANTONELLA MARIANO<sup>1</sup>, RICCARDO SANTINI<sup>1</sup>, GIACOMO CIOCCA<sup>3,4</sup>, EMMANUELE A. JANNINI<sup>4</sup>, ALBERTO SIRACUSANO<sup>1</sup>, CINZIA NIOLU<sup>1</sup>**

<sup>1</sup>Chair of Psychiatry, Department of Systems Medicine, University of Rome Tor Vergata, Rome, Italy; <sup>2</sup>IRCCS – Fondazione Santa Lucia, Rome, Italy; <sup>3</sup>Department of Dynamic and Clinical Psychology, Sapienza University of Rome, Italy; <sup>4</sup>Chair of Endocrinology & Medical Sexology (ENDOSEX), Department of Systems Medicine, University of Rome Tor Vergata, Italy.

**Summary. Introduction.** Priapism is defined as a prolonged penile erection in absence of sexual arousal, leading also to serious sexual and urological problems such as erectile dysfunction and penile fibrosis. Amongst many different etiologies, priapism may be caused by a wide range of antipsychotic medications, mainly due to the  $\alpha$ 1-adrenergic receptor antagonism. On the other hand, only a couple of cases of opioid compounds have been linked to the onset of priapism, with evidence coming only from methadone and buprenorphine. Here we describe the case of a patient treated with antipsychotics who developed priapism four times following rapid discontinuation of buprenorphine/naloxone (Suboxone®). **Case presentation.** S.C. is a 30-year-old Caucasian man suffering from chronic buprenorphine/naloxone (Suboxone®) abuse, borderline personality disorder, antisocial traits, and multiple suicide attempts. During the acute and the first part of post-acute Suboxone® withdrawal, four episodes of priapism developed while he was treated with clotiapine, clozapine, and chlorpromazine. However, after the last episode of priapism, despite he was either on haloperidol or zuclopenthixol and chlorpromazine, no other urological event occurred during the following 6 months of observation. **Conclusions.** As opioids may have dampened the patient's sexual function due to chronic consumption, a rapid drug suspension coupled with an antipsychotic therapy might have created the conditions to facilitate the occurrence of close clustered priapism events.

**Key words.** Antipsychotics, buprenorphine, case report, priapism, withdrawal.

*L'astinenza da buprenorfina/naloxone (Suboxone®) può facilitare il priapismo indotto da antipsicotici. Un caso clinico.*

**Riassunto. Introduzione.** Il priapismo viene definito come un'erezione peniena prolungata in assenza di eccitazione sessuale, che può comportare gravi problemi urologici e sessuali, come per esempio la disfunzione erettile e la fibrosi del pene. Tra le diverse eziologie, il priapismo può essere causato da un'ampia gamma di farmaci antipsicotici, soprattutto a causa dell'antagonismo del recettore  $\alpha$ 1-adrenergico che questi esercitano. A oggi, solo pochi casi di composti oppioidi sono stati collegati all'insorgenza di priapismo, con evidenze provenienti esclusivamente dal metadone e dalla buprenorfina. Il caso qui presentato descrive un paziente trattato con antipsicotici che ha sviluppato priapismo quattro volte dopo una rapida interruzione di buprenorfina/naloxone (Suboxone®). **Presentazione del caso.** S.C. è un uomo caucasico di 30 anni che soffre di un abuso cronico di buprenorfina/naloxone (Suboxone®), disturbo borderline di personalità, con tratti antisociali e multipli tentativi di suicidio. Durante l'astinenza acuta di Suboxone® e la prima fase post-acute, il paziente ha sviluppato quattro episodi di priapismo mentre era in trattamento con clotiapina, clozapina e clorpromazina. Tuttavia, dopo l'ultimo episodio di priapismo, nonostante fosse in terapia con aloperidolo o zuclopentixolo e clorpromazina, nei successivi 6 mesi di osservazione non si è verificato nessun altro evento urologico. **Conclusioni.** Poiché il consumo cronico di oppioidi può aver colpito la funzionalità sessuale del paziente, una rapida sospensione del farmaco associata a una terapia antipsicotica potrebbe aver creato le condizioni per facilitare il verificarsi di eventi di priapismo a cluster ravvicinati.

**Parole chiave.** Antipsicotici, astinenza, buprenorfina, caso clinico, priapismo.

### **Introduction**

Priapism is a dangerous urological emergency that consists in a prolonged penile erection, lasting for more than 4 hours despite the absence of sexual arousal. Extra caution has to be given when dealing with such a condition, as the consequent anoxia may

lead to serious long-lasting sequelae such as erectile dysfunction, necrosis and loss of cavernous tissue, and eventually permanent fibrosis<sup>1</sup>.

Priapism may be triggered by different medical conditions, like sickle-cell anemia and leukemia, or recreational drugs like alcohol and cocaine<sup>2</sup>. Among the drugs of abuse, only a couple of cases of opioid compounds have been linked to the onset of pri-

pism, with evidence coming only from methadone<sup>3</sup> and buprenorphine<sup>4</sup>. On the other hand, many psychotropic medications may be responsible for a consistent number of cases. Indeed, besides trazodone, fluoxetine, and bupropion, both typical and atypical antipsychotic drugs are, among a plethora of different treatment-emergent adverse side effects, associated with priapism<sup>5-9</sup>. Among these, only a few case studies reported clozapine-induced priapism<sup>10,11</sup>, and no clotiapine-related event has been presented so far. The pathophysiology is still largely unknown; however, the  $\alpha$ 1-receptor blockade has been described as a possible mechanism of action in medication-induced priapism<sup>12</sup>.

Here we describe the case of a patient treated with antipsychotics who developed priapism four times following rapid discontinuation of buprenorphine/naloxone (Suboxone®).

---

## Case presentation

S.C. is a 30-year-old Caucasian male with a long chronic opioid abuse (Suboxone® sublingual tablets, buprenorphine 16 mg / naloxone 4 mg), and borderline personality disorder (BPD) with antisocial traits clinical history.

Due to worsening acts of self-harm and multiple suicide attempts, the patient was referred to our Psychiatry Unit with the following pharmacotherapy: clozapine 125 mg/day, clotiapine 90 mg/day, sodium valproate 1500 mg/day, and clonazepam 4 mg/day. On the second day after the hospitalization, he developed ischemic priapism, which was treated with an etilefrine penile injection, aspiration, and compression bandage. Clozapine was then gradually reduced to 50 mg/day.

Twelve days after the admission, the patient reported two other episodes of priapism on the same day. Both of them were treated similarly as described for the first episode. Clozapine and clotiapine were then gradually interrupted and cross-tapered to amisulpride 600 mg/day.

Progressively, the patient passed from acute to a post-acute withdrawal phase, reporting post-acute withdrawal symptoms with a constant craving for drugs, food, and beverages, feelings of anxiety, and increasing opposition. Fluctuant and, sometimes, intense psychotic symptoms were also featured intensively during this phase. Thus, on day 33 after the hospitalization, chlorpromazine 150 mg/day was then added to therapy.

At night-time of day 45, the patient experienced feelings of restlessness and total insomnia: clotiapine 100 mg as an on-demand therapy was established. On the morning after, 34 days from the last priapism episode, the patient complained of the onset of an-

other permanent penile erection, which was treated as previously. Both chlorpromazine and clotiapine were then discontinued.

After 60 days from the hospitalization, the patient reported an intensification of psychotic symptoms; therefore, amisulpride was interrupted and cross-tapered to haloperidol 6 mg/day *per os*. Starting from day 165, due to moderate agitation and psychotic symptoms, haloperidol was gradually switched to zuclopenthixol 200 mg/day and chlorpromazine 150 mg/day. On days 181, 185, and 187 three new episodes of severe psychomotor agitation, with an intensification of psychotic symptoms were successfully treated with clotiapine 60 mg as an on-demand therapy. Nevertheless, after the last episode of priapism, despite he was either on haloperidol or zuclopenthixol and chlorpromazine, no other urological events occurred during the following 6 months. Both sodium valproate and clonazepam were maintained for the whole duration of the observation (figure 1).

---

## Discussion

The present case report shows a patient with an opioid use disorder that was treated with antipsychotic medications and developed priapism. To our knowledge, the patient's past medical history did not report any blood dyscrasias, leukemia, sickle cell anemia, or spinal cord injuries that could have elicited or enhanced this urological emergency.

Typical and atypical antipsychotics may cause priapism due to their  $\alpha$ 1-adrenergic receptor antagonism, which leads to vessel dilation, impaired venous drainage, higher intracavernosal blood pressure, and eventually erection. Since serious sequelae may arise after prolonged ischemic conditions, prompt intervention with sympathomimetic injections must be established as quickly as possible<sup>13</sup>.

Clozapine-induced priapism is an extremely rare condition, as only a little evidence is present in the literature. When priapism occurred once, clozapine was not stopped, as previous evidence has shown a successful treatment without drug discontinuation<sup>14</sup>.

To the best of our knowledge, the present clinical case is the first showing clotiapine as a possible contributor to the onset of priapism. Clotiapine, whose pharmacological properties are similar to chlorpromazine and clozapine, is an extremely sedating dibenzothiazepine antipsychotic, mainly used in the acute phase of psychomotor agitation<sup>15</sup>. Previous evidence has pointed out how clotiapine acts also through an  $\alpha$ 1-receptor antagonism, therefore addressing this compound as a possible trigger<sup>16</sup>.

Although the patient was conjointly taking amisulpride, we believe the on-demand clotiapine to be the *genuine* trigger of priapism of day 45, as no uro-

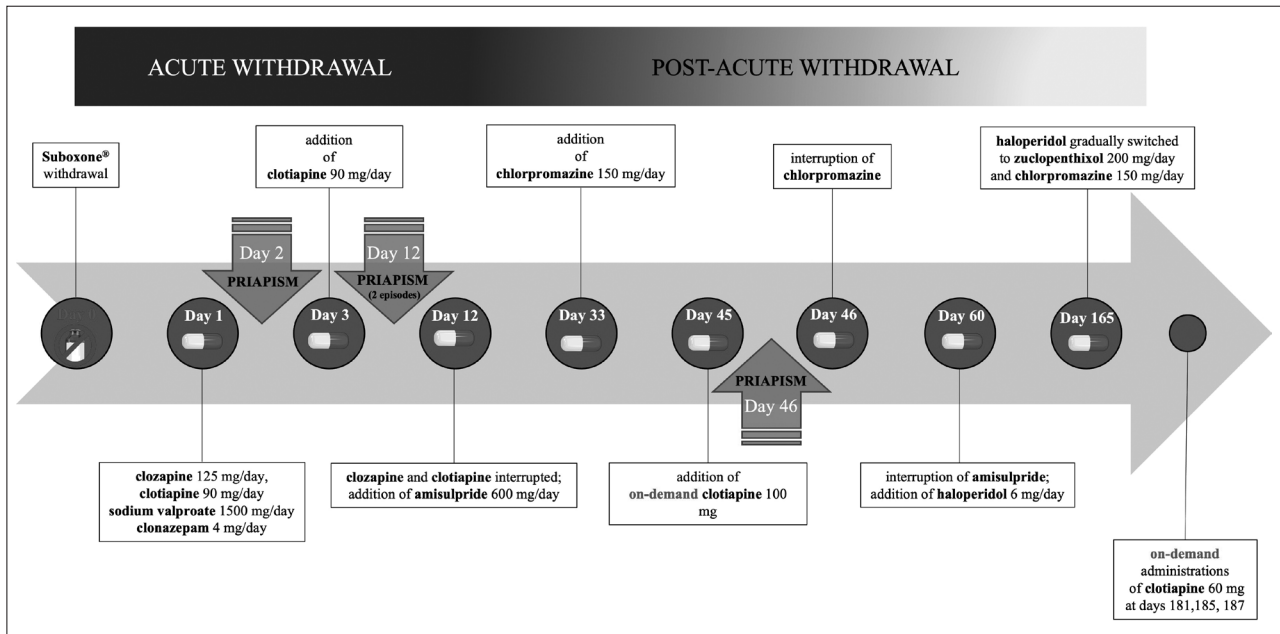


Figure 1. Flow-chart summarizing patient's clinical course.

logical event was reported from days 12 to 45, i.e., when clotiapine was established. The decision of adding amisulpride was supported by the evidence that this compound does not show any affinity to  $\alpha_1$ -adrenoceptors<sup>17</sup>.

Interestingly, the patient was a chronic Suboxone® abuser. Suboxone® is a combination of buprenorphine and naloxone used to treat adults who are addicted to opioid drugs. Chronic use of opioids like buprenorphine is well-known to cause, besides gastrointestinal, neurologic, and respiratory issues, also sexual dysfunctions, e.g. hypogonadism<sup>18</sup>. On the other hand, early studies have emphasized how naloxone, an opioid-receptor antagonist, has a positive effect on sexual behavior, improving sexual function in patients with idiopathic impotence<sup>19</sup>. However, a possible implication of naloxone in the present clinical scenario has to be considered unlikely for two orders of reasons. On the one hand, the absorption of naloxone is very minimal due to the poor bioavailability and is only meaningfully increased in the setting of severe hepatic failure. On the other hand, this compound has a very short half-life<sup>20</sup>. Nonetheless, an interesting explanation may be provided by the link with the acute withdrawal syndrome following rapid discontinuation of buprenorphine/naloxone when the patient was hospitalized. Indeed, symptoms of withdrawal featured, besides influenza-like symptoms, shaking, high blood pressure, psychomotor agitation, and verbal aggressiveness, also a strong craving for Suboxone®<sup>21</sup>. Due to the long-lasting history of Suboxone® abuse, these symptoms lasted for a consistent amount of time, defining this condition

as a post-acute withdrawal syndrome (PAWS). PAWS comprises symptoms that are still present and persist for weeks or months after the acute phase of abstinence has resolved<sup>22</sup>.

As opioids may have dampened sexual function due to chronic consumption, a sudden suspension coupled with an intense antipsychotic  $\alpha_1$ -adrenergic blockade might have created the conditions to facilitate the occurrence of clustered priapism events. During the acute phase of the withdrawal syndrome, he reported 3 priapism episodes in twelve days (two of them in the same day), whereas when entering the PAWS only one episode was registered. Remarkably, these observations agree with two case reports of patients with opioid use disorder treated with antipsychotics, which reported episodes of priapism potentially consequent to the use of methadone and buprenorphine<sup>3,4</sup>.

Consistent with our interpretation, after the last priapism episode and during the following 6 months of observation, the patient did not report any withdrawal symptoms, nor any other urological event, despite he was subsequently treated with haloperidol, zuclopenthixol, and chlorpromazine. These compounds can indeed cause priapism, as butyrophenones, thioxanthenes, and phenothiazines are known to express a low (adjusted affinity for the  $\alpha_1$  receptor =  $5.9 \cdot 10^7 M^{-1}$ ), intermediate ( $37.0 \cdot 10^7 M^{-1}$ ) and high ( $38.5 \cdot 10^7 M^{-1}$ ) degree of affinity to  $\alpha_1$ -receptors, respectively<sup>17,23</sup>. In addition, unlike day 45, on-demand administrations of clotiapine 50 mg during the last episodes of psychomotor agitation did not elicit any priapism event. However, a few limitations must be

addressed in our interpretation. Firstly, since withdrawals from buprenorphine would generally cause sympathetic activation, seemingly negating some risks for inducing priapism, which is caused by  $\alpha 1$  antagonism, we cannot conclude Suboxone® to be the actual responsible for such urological events. To this end, we also performed the Naranjo scale algorithm for each substance that we considered involved in the pathogenesis of priapism events. A total score of 3 for Suboxone® and of 4 for each of the antipsychotic drugs ascribes both compounds within the range of possibility ( $\leq 0$  = doubtful; 1-4 = possible; 5-8 = probable;  $\geq 9$  = definite)<sup>24</sup>. Hence, this does not allow to precisely discriminate which of them has actually caused such adverse reaction. Furthermore, as priapism has to be considered idiosyncratic and no clear cause-effect mechanism can be addressed, adverse effects may differ from patient to patient.

## Conclusions

The present case report allows hypothesizing that buprenorphine/naloxone withdrawal, especially when coupled with antipsychotic therapies, may favor a paroxysmal penile vascular response leading to priapism. This underscores how extra caution should be paid when administering such compounds to patients with a recent history of opioid abuse.

*Consent for publication:* the patient's written informed consent was obtained for the publication of the present case report.

*Competing interest:* the authors declare that they have no conflict of interest.

*Authors' contribution:* TB: patient's information collection, manuscript drafting; GDL: diagnostic interpretation, manuscript critical revision; AM: patient's information collection; RS, GC: literature review; EAJ: manuscript critical revision; AS: manuscript critical revision; CN: diagnostic interpretation, manuscript critical revision. All authors have read and approved the final manuscript.

## References

- Mishra K, Loeb A, Bukavina L, et al. Management of priapism: a contemporary review. *Sex Med Rev* 2020; 8: 131-9.
- Offenbacher J, Barbera A. Penile emergencies. *Emerg Med Clin North Am* 2019; 37: 583-92.
- Mostafavi SA, Bidaki R. Priapism Followed by discontinuation of methadone: a rare case report. *Iran J Psychiatry* 2015; 10: 133-5.
- Sinkeviciute I, Kroken RA, Johnsen E. Priapism in antipsychotic drug use: a rare but important side effect. *Case Rep Psychiatry* 2012; 2012: 496364.
- Scherzer ND, Reddy AG, Le TV, Chernobylsky D, Hellstrom WJG. Unintended consequences: a review of pharmacologically-induced priapism. *Sex Med Rev* 2019; 7: 283-92.
- Ciocca G, Jannini TB, Ribolsi M, et al. Sexuality in ultra-high risk for psychosis and first-episode psychosis. A systematic review of literature. *Front Psychiatry* 2021; 12: 750033.
- Hwang T, Shah T, Sadeghi-Nejad H. A review of antipsychotics and priapism. *Sex Med Rev* 2021; 9: 464-71.
- Mariano A, Di Lorenzo G, Jannini TB, et al. Medical comorbidities in 181 patients with bipolar disorder vs. schizophrenia and related psychotic disorders: findings from a single-center, retrospective study from an Acute Inpatients Psychiatric Unit. *Front Psychiatry* 2021; 12: 702789.
- Jannini TB, Rossi R, Sconci V, et al. Italian validation of Arizona Sexual Experience Scale (ASEX) on patients suffering from psychotic spectrum disorders. *Riv Psichiatr* 2022; 57: 18-22.
- Casiano H, Globerman D, Enns MW. Recurrent priapism during treatment with clozapine, quetiapine and haloperidol. *J Psychopharmacol* 2007; 21: 898-9.
- Donizete da Costa F, Toledo da Silva Antonialli K, Dalgalarondo P. Priapism and clozapine use in a patient with hypochondriacal delusional syndrome. *Oxf Med Case Reports* 2015; 2015: 229-31.
- Svensson TH. Alpha-adrenoceptor modulation hypothesis of antipsychotic atypicality. *Prog Neuropsychopharmacol Biol Psychiatry* 2003; 27: 1145-58.
- Levey HR, Segal RL, Bivalacqua TJ. Management of priapism: an update for clinicians. *Ther Adv Urol* 2014; 6: 230-44.
- de Nesnera A. Successful treatment with clozapine at higher doses after clozapine-induced priapism. *J Clin Psychiatry* 2003; 64: 1394-5.
- Carpenter S, Berk M, Rathbone J. Clotiapine for acute psychotic illnesses. *Cochrane Database Syst Rev* 2004; (4): CD002304.
- Perez Raya MD, Zarzuelo A, Duarte JM, Jimenez J, Navarro C. Chlorpromazine and clothiapine actions at the level of the CNS and vas deferens. *Pharm Acta Helv* 1990; 65: 228-32.
- Leysen JE, Janssen PM, Schotte A, Luyten WH, Megens AA. Interaction of antipsychotic drugs with neurotransmitter receptor sites in vitro and in vivo in relation to pharmacological and clinical effects: role of 5HT2 receptors. *Psychopharmacology* 1993; 112 (1 Suppl): S40-54.
- Marudhai S, Patel M, Valaiyaduppu Subas S, et al. Long-term opioids linked to hypogonadism and the role of testosterone supplementation therapy. *Cureus* 2020; 12: e10813.
- Fabbri A, Jannini EA, Gnassi L, et al. Endorphins in male impotence: evidence for naltrexone stimulation of erectile activity in patient therapy. *Psychoneuroendocrinology* 1989; 14: 103-11.
- Clemency BM, Eggleston W, Lindstrom HA. Pharmacokinetics and pharmacodynamics of naloxone. *Acad Emerg Med* 2019; 26: 1203-4.
- Westermeyer J, McCance-Katz EF. Course and treatment of buprenorphine/naloxone withdrawal: an analysis of case reports. *Am J Addict* 2012; 21: 401-3.
- Le Merrer J, Befort K, Gardon O, et al. Protracted abstinence from distinct drugs of abuse shows regulation of a common gene network. *Addict Biol* 2012; 17: 1-12.
- Andersohn F, Schmedt N, Weinmann S, Willich SN, Garbe E. Priapism associated with antipsychotics: role of alpha1 adrenoceptor affinity. *J Clin Psychopharmacol* 2010; 30: 68-71.
- Naranjo CA, Busto U, Sellers EM, et al. A method for estimating the probability of adverse drug reactions. *Clin Pharmacol Ther* 1981; 30: 239-45.

Corresponding author:  
Giorgio Di Lorenzo, MD, PhD  
Chair of Psychiatry  
Department of Systems Medicine  
University of Rome Tor Vergata  
Via Montpellier 1  
00133 Rome, Italy  
E-mail: di.lorenzo@med.uniroma2.it