

Similar grey matter abnormalities in 22q11.2DS and chronic schizophrenia: a voxel-based morphometry study

MARIANNA FRASCARELLI¹, TOMMASO ACCINNI¹, ANTONINO BUZZANCA¹, CARLO DI BONAVENTURA¹, MARTINA FANELLA¹, CAROLINA PUTOTTO², BRUNO MARINO², MASSIMO PASQUINI¹, MASSIMO BIONDI¹, CLAUDIO COLONNESE¹, FABIO DI FABIO¹

¹Department of Human Neurosciences, Sapienza University of Rome, Italy; ²Department of Pediatrics, Obstetrics and Gynecology, Sapienza University of Rome, Italy.

Summary. Background. The 22q11.2 Deletion Syndrome (22q11.2DS) is considered the most reliable biological model to study genetic vulnerability to schizophrenia. It appears useful to investigate neuroanatomical characteristics of people with 22q11.2DS compared to chronic schizophrenia and healthy controls. **Methods.** The sample consisted of 16 individuals with a diagnosis of schizophrenia for over 10 years (SCZ>10), 14 with a diagnosis for less than 10 years (SCZ≤10), 11 patients with 22q11.2DS with no diagnosis of psychotic disorder (DEL, n=11) and 19 healthy controls (HCs, n=19). Global intelligence (IQ) was evaluated for all subjects. Voxel-Based Morphometry (VBM) was employed to investigate potential differences between groups in grey matter volumes. **Results.** VBM located the most significant difference between SCZ and HCs in the left medial frontal gyrus, where SCZ>10 group showed a significant reduction of grey matter volume; the same cluster resulted significantly decreased in DEL group compared to HCs as well. Despite the extensive grey matter abnormalities observed in 22q11.2DS, the DEL group showed the only significant differences compared to the SCZ>10 group in the right lingual gyrus volumes. **Conclusions.** Despite the small sample, our study identified a common area of grey matter loss both in idiopathic schizophrenia and 22q11.2DS.

Key words. 22q11.2 deletion syndrome, high-risk, psychosis, VBM, velocardio-facial syndrome, vulnerability.

Introduction

The microdeletion of the band 11.2 in the chromosome 22 is the most common among rare Copy Number Variations (CNVs) in humans, determining the 22q11.2 Deletion Syndrome (22q11.2DS) which is expressed in 1:4000 live birth¹. 22q11.2DS has a 100% of penetrance but the phenotypic expression

Alterazioni della materia grigia in comune tra la 22q11.2DS e la schizofrenia cronica: uno studio di morfometria voxel-based.

Riassunto. Introduzione. La sindrome da delezione del cromosoma 22q11.2 (22q11.2DS) è considerata il modello biologico più affidabile per lo studio della vulnerabilità genetica alla schizofrenia. Pertanto, risulta utile una comparazione tra le caratteristiche neuroanatomiche di individui con 22q11.2DS, pazienti con schizofrenia cronica e controlli sani. **Metodi.** Il campione reclutato consisteva in 16 individui con diagnosi di schizofrenia da più di 10 anni (SCZ>10), 14 con una diagnosi di schizofrenia da meno di 10 anni (SCZ≤10), 11 pazienti affetti da 22q11.2DS senza diagnosi di disturbo psicotico (DEL, n=11) e 19 controlli sani (HCs, n=19). Per ogni soggetto reclutato è stato calcolato il quoziente intellettivo (QI). È stata effettuata un'indagine di morfometria voxel-based (VBM) al fine di investigare eventuali differenze tra i gruppi riguardo alla materia grigia. **Risultati.** Le indagini con la VBM hanno individuato a livello del giro frontale mediale la differenza più significativa tra il gruppo SCZ e il gruppo HCs; in particolare il gruppo SCZ>10 ha mostrato una significativa riduzione del volume della materia grigia. Il medesimo cluster è risultato significativamente ridotto nel gruppo DEL in confronto ai controlli sani. Nonostante il rilevante grado di anomalie della materia grigia riscontrato nella 22q11.2DS, il gruppo DEL ha mostrato delle differenze significative in confronto al gruppo SCZ>10 unicamente in relazione ai volumi del giro linguale destro. **Conclusioni.** Nonostante il ridotto numero campionario, il presente studio ha identificato una comune area di riduzione della materia grigia tanto nei soggetti con 22q11.2DS quanto in coloro con schizofrenia idiopatica.

Parole chiave. Alto-rischio, psicosi, sindrome da delezione del cromosoma 22q11.2, sindrome velo-cardio facciale, VBM, vulnerabilità.

is highly protean with all clinical features stemming from neural crest cells during embryo development²: facial dysmorphias, cardiovascular congenital abnormalities, palatal defects, thymus hypoplasia with primary immunodeficiency, ipoparathyroidism are involved³. Individuals with 22q11.2DS present motor delay, learning disabilities and language difficulties⁴. Mathematical reasoning⁵ and visuo-spatial abilities⁶ appear often impaired and deficits in sustained attention, executive functions and

working memory⁷ have been reported. A borderline intellectual disability (IQ from 70 to 84) has been described⁸. Social difficulties, impulsiveness and shyness characterize 22q11.2 microdeletion carriers' temperament⁹. 22q11.2DS represents the most reliable biological model to study genetic vulnerability to schizophrenia: indeed, the microdeletion of the band 11.2 in the chromosome 22 gives a 25% increased risk of developing a psychotic disorder¹⁰. More recently, the prevalence of schizophrenia spectrum disorders in 22q11DS has been attested ranging from 23% to 43% depending on studies^{11,12}; the International Consortium on Brain and Behaviour in 22q11.2 Deletion Syndrome¹³ demonstrated in a sample of 1402 individuals with 22q11.2DS¹² a 41% prevalence of schizophrenia in subjects with age \leq 25 years, confirming that 22q11.2 microdeletion is the most robust known genetic risk factor for schizophrenia. Of note, psychotic manifestations in 22q11.2DS do not significantly differ from idiopathic schizophrenia, in regard of positive and negative symptoms, neurocognitive profile, age of onset and global functioning^{10,14,15}. The opportunity of such a biological model might be helpful to deepen the neurobiological underpinnings of psychotic disorders and to describe their prodromal phases as well. It has been observed that genes in the 11.2 band of chromosome 22 are involved in neurodevelopment and their aplodeficiency seems to cause an abnormal brain maturation likely influencing the behavioural, neurocognitive and psychopathological phenotype of the syndrome^{16,17}: these genes' polymorphisms could contribute more widely to determine vulnerability to schizophrenia in general population.

Numerous studies and meta-analyses had repeatedly acknowledged diffuse grey matter abnormalities in schizophrenia, affecting the insula, the anterior cingulate cortex, some medial temporal structures like the amygdala and the para-hippocampal gyrus, the thalamus, the superior temporal gyrus and the inferior frontal gyrus¹⁸⁻²⁰. In recent years, Voxel-Based Morphometry (VBM)²¹, an automated whole brain method for structural imaging analysis, has been extensively employed to discover loci of abnormal grey matter volume in schizophrenia, avoiding the potentially biased Region of Interest methodology. A systematic review of 48 VBM based studies²² found volume reductions in brains of patients with schizophrenia compared to healthy controls concerning the following cortical regions: the insula, the inferior frontal gyrus, the thalamus and the anterior cingulate cortex; these alterations may represent biological endophenotypes of schizophrenia appearing associated to its prodromal phases²³. As revealed by a meta-analysis²⁴ enrolling 458 subjects at high genetic risk for schizophrenia and 206 subjects at first

episode of psychosis, the genetic predisposition to psychosis appeared associated with a significant volume reduction of the anterior cingulate gyrus, while the onset of a full-blown psychosis with a reduction of the cerebellum and the superior temporal gyrus. A meta-analysis of VBM based studies found a progressive reduction in volumes of frontal areas according to the illness progression²⁵, as observed comparing at-risk individuals, first episode subjects and chronic patients with schizophrenia. Longitudinal studies²⁶ have distinguished neuroimaging findings based on the type of risk for psychosis: they revealed volume reductions in the para-hippocampal region regarding people with a clinical Attenuated Psychotic Syndrome (APS), in the right cerebellum and in the inferior temporal gyrus for individuals with a genetic load for psychosis. Interestingly, genetic polymorphisms associated to vulnerability to schizophrenia seem to impact on both grey and white matter volumes, likely influencing an accelerated neuron loss during the lifetime^{23,27}. The Duration of Illness (DoI) showed an inverse correlation with the volume of prefrontal²⁸⁻³⁰ and temporal^{30,31} regions, suggesting that symptoms' expression modulates progressive brain structural changes in schizophrenia.

Neuroimaging abnormalities in 22q11.2DS have been investigated as well and a meta-analysis³² of 22 structural MRI based studies reported in this syndrome a global brain volume reduction comparing 626 patients with the syndrome to 576 healthy controls: in particular a decrease of grey matter volumes in frontal, parietal, temporal and occipital lobes and a diminished integrity of temporal and occipital white matter. Moreover, the cerebellum and the corpus callosum volumes appeared reduced in 22q11.2DS and a rostro-caudal gradient in children was observed: frontal regions where the most reduced, followed by temporal, cerebellar and occipital regions at last. These findings, consistently to evidence about idiopathic schizophrenia, would confirm the hypothesis of an early abnormal neurodevelopment²⁷. Evidence is accumulating that neuroanatomical regions typically affected in idiopathic schizophrenia are involved in psychotic patients with 22q11.2DS too, as observed for the reduced volume of the temporal lobe³²; furtherly, lower frontal and medial temporal volumes were associated with a higher risk of developing psychosis in adolescents with 22q11.2DS³³ while a bilateral volume decrement in temporal lobe was confirmed to correlate with psychosis in 22q11.2DS³⁴. Bearing this evidence in mind, it appears useful to investigate neuroanatomical differences between subjects with idiopathic schizophrenia and people at genetic risk for psychosis as individuals with 22q11.2DS, considering that such studies are still lacking.

Objectives

The present study was aimed at investigating potential grey matter abnormalities in individuals with 22q11.2DS. The second aim of the study was to ascertain whether potential neuroanatomical abnormalities in 22q11.2DS were like the ones ascertained in idiopathic schizophrenia: a Voxel-Based Morphometry was employed to test the hypothesis that individuals with 22q11.2DS without psychosis show reduced volumes of grey matter in specific brain regions similarly to idiopathic schizophrenia and differing from healthy controls.

Methods

SUBJECTS

The sample consisted of 30 patients with a diagnosis of schizophrenia without 22q11.2DS (SCZ, N=30), 11 patients with 22q11.2DS with no diagnosis of psychotic disorder (DEL, N=11) and 19 healthy controls with typical development (HCs, N=19); apart from the latter who joined the study by word of mouth, all participants have been consecutively enrolled from the Psychotic Disorders Outpatient Clinic of the Department of Human Neurosciences of the Hospital Policlinico Umberto I, in Rome. For statistical analysis, the SCZ group was furtherly divided in two separated groups depending on the average DoI: 16 individuals with a diagnosis of schizophrenia for over 10 years (SCZ>10) and 14 with a diagnosis for less than 10 years (SCZ≤10). Individuals of SCZ and HC groups took part in a previous study that demonstrated how specific volume reduction in medial frontal cortex observed in SCZ group depended on illness duration³⁵. Patient eligibility and diagnosis of psychotic disorder were based on the Structured Clinical Interview for DSM-IV Axis I Disorders/Patient Edition (SCID-I /P), with the aim to investigate the presence of other previous or current psychiatric symptomatology that would meet criteria for a DSM-5 diagnosis. Genetic diagnosis was ascertained through Fluorescent *In Situ* Hybridization (FISH). The study adopted the Principles of Human Rights, as issued by the World Medical Association at the 18th WMA General Assembly, Helsinki, Finland, June 1964 and subsequently amended by the 64th WMA General Assembly, Fortaleza, Brazil, in October 2013. The research protocol has been reviewed and approved by the Ethics Committee of the Umberto I University Hospital, Rome, Italy. All data were anonymized, and all subjects signed a written informed consent.

CLINICAL AND COGNITIVE ASSESSMENT

General intelligence was assessed in all subjects through IQ measurement by the Wechsler Adult Intelligence Scale³⁶ (WAIS). For all SCZ patients, symptomatology and global functioning were assessed respectively with the Positive And Negative Syndrome Scale³⁷ (PANSS) and the Global Assessment of Functioning³⁸ (GAF). The number of hospitalizations during the history of illness and the dosage of antipsychotic treatment (Chlorpromazine Equivalents) at the present date were collected as well.

IMAGE ACQUISITION

All recruited subjects underwent brain imaging using a Siemens Verio 3T MRI scanner at the Policlinico Umberto I in Rome (Italy). T1 structural images encompassing the whole brain were collected from all subjects using the following parameters: repetition time= 2300 ms; echo time= 298 ms; inversion time= 900 ms; flip angle= 91; slice thickness= 1 mm; voxel size= 1 x 1 x 1; number of slices= 298.

IMAGE ANALYSIS

Data were available for the entire sample. Group-related differences in grey matter volume (GMV) were examined using Voxel-Based Morphometry (VBM), as implemented in SPM8 software (<http://www.fil.ion.ucl.ac.uk/spm>) running under MATLAB 8.1 (The MathWorks, Inc, Natick, MA). Firstly, T1-weighted volumetric images were pre-processed using the diffeomorphic anatomical registration through exponentiated lie algebra (DARTEL)³⁹ SPM8 toolbox. This approach involves a study-specific template and the segmentation of each individual image according to this model to maximize accuracy and sensitivity⁴⁰. VBM pre-processing involved: 1) checking for scanner artefacts and gross anatomical abnormalities for each subject; 2) setting the images' origin to the anterior commissure; 3) using the DARTEL toolbox to produce a high dimensional normalization protocol⁴⁰; 4) checking for homogeneity across the sample; 5) using standard smoothing (i.e., 8 mm). A "modulation step" was also included in the normalization to preserve the information about the absolute grey matter values^{21,41}. After this pre-processing step, smoothed, modulated, and normalized data were obtained, then they have been used for the statistical analysis. Total grey and white volume was calculated for all subjects. An Analysis of Variance (ANOVA) was performed in SPM8 to compare the four groups in a whole brain analysis, with gender and age entered as nuisance covariates. Statistical inferences were made at p<0.05 after family-wise error (FWE) correction for multiple comparisons. If no results were observed for p<0.05 FWE, a p value of p<0.001 uncorrected

was considered. A $k=5$ threshold was employed, so that only clusters with more than 5 voxels were conserved. Plot function from SPM8 was employed to extract Volume of Interest (VOI) from a single coordinate (VOI, $r=8$).

STATISTICAL ANALYSIS

Descriptive statistics were implemented for socio-demographical variables and IQ. Group differences have been examined by ANOVA or t-test for continuous variables, and through χ^2 -test for categorical variables. Post-hoc were corrected for multiple comparisons with Bonferroni. Statistical analyses were run on IBM SPSS20 on Windows®.

Results

SOCIO-DEMOGRAPHICAL AND CLINICAL DIFFERENCES BETWEEN GROUPS

Sample characteristics are illustrated in table 1.

Recruited groups did not show significant differences in gender composition. A significant difference between groups was observed for mean age: post-hoc analysis showed that SCZ>10 group was significantly

older compared to any other group ($p<0.001$). HCs group showed a higher IQ compared to the clinical groups ($p<0.001$). On the contrary, post-hoc analysis did not show significant differences in average IQ between the SCZ<10, SCZ>10 and DEL groups. The DEL group showed a higher global functioning compared to SCZ>10 group ($p=0.005$), but any significant difference compared to SCZ<10 group was observed. Regarding the SCZ group, DoI did not show significant influences on global functioning (GAF) or symptoms' severity (PANSS). The two SCZ groups did not significantly differ neither regarding the number of hospitalizations during their illness history, nor the dosage of antipsychotic treatment at the moment of the study assessment.

VOXEL-BASED MORPHOMETRY RESULTS

No significant differences were observed in total grey matter or total white matter volumes between recruited groups (table 2), which is why we did not insert total GM and total WM as covariates in the statistical analysis.

At a whole brain level, the ANOVA analysis showed significant differences between the four recruited groups in the following grey matter regions: the left medial frontal gyrus (19 voxels: MNI coordinates $x=-11, y=32, z=34$;

Table 1. Descriptive statistics and ANOVA results for clinical and socio-demographical characteristics.

	HC (n=19)		SCZ≤10 (n=14)		SCZ>10 (n=16)		DEL (n=11)		Test statistic	
<i>Categorical variable</i>										
	N	%	N	%	N	%			χ^2	p
Gender										
Males	6	31.6	6	42.9	9	56.2	9	81.8	7.569	0.056
Females	13	68.4	7	57.1	7	43.8	2	18.2		
<i>Continue variables</i>										
	Mean	SD	Mean	SD	Mean	SD	Mean	SD	F	p
Age	29.7	9.1	29.4	8.5	43.1	7.4	24.9	8.0	13.039	<0.001*
PANSS										
Positive	7	0	15.9	5.5	15.3	6.0	8.4	2.0	18.972	<0.001*
Negative	7	0	22.2	7.2	24.4	9.3	9.7	2.4	33.786	<0.001*
General	18.3	1.9	39.4	9.7	40.1	8.9	27.5	4.7	38.146	<0.001*
Total	32.3	2.0	77.5	19.9	79.8	20.0	45.7	8.0	42.538	<0.001*
GAF	91.1	2.1	54.6	14.9	50.7	13.2	65.8	10.7	48.309	<0.001*
IQ Tot	113.0	11.1	94.4	23.5	86.6	15.0	91.6	11.7	9.243	<0.001*
									t	p
Illness duration			4.9	3.5	17.2	5.1			-8.197	<0.001*
CPZ Eq			302.7	167.9	369	243.3			-0.922	0.363
Admissions			1.5	1.9	1.7	2			-0.247	0.807

Table 2. Descriptive statistics and ANOVA results for total grey matter volumes (GM) and total white matter volumes (WM).

	HC (n=19)		SCZ<10 (n=14)		SCZ>10 (n=16)		DEL (n=11)		F	p
	Mean	SD	Mean	SD	Mean	SD	Mean	SD		
GM	680	63	684	71	665	96	654	68	0.444	0.723
WM	490	56	495	44	495	78	470	47	0.499	0.684

F=15.90, $p=0.003$ FWE), the right lingual gyrus (69 voxels; MNI coordinates $x=12, y=-82, z=-12$; F=14.15, $p=0.011$ FWE), the left culmen of the cerebellum (10 voxels; MNI coordinates $x=-14, y=-37, z=-14$; F=12.73, $p=0.029$ FWE), the left cuneus (7 voxels; MNI coordinates $x=-5, y=-76, z=4$; F=12.32, $p=0.029$ FWE) (figure 1).

However, the ANOVA results are poorly indicative about the direction of the between groups differences. Indeed, we implemented twelve contrasts in which each group was subsequently compared with the others. Clusters of voxels resulted from each contrast in which the group being compared showed an excess of gray matter compared with the other group. Results from each contrast (MNI coordinates and statistical test) are reported in table 3.

HCs versus SCZ<10

No voxels were significant for $p<0.05$ FWE. According to a less conservative threshold ($p\leq 0.001$ uncorrected), HCs group showed higher grey matter volumes in the right superior temporal gyrus, in the left middle occipital gyrus and in the left inferior occipital gyrus (table 3).

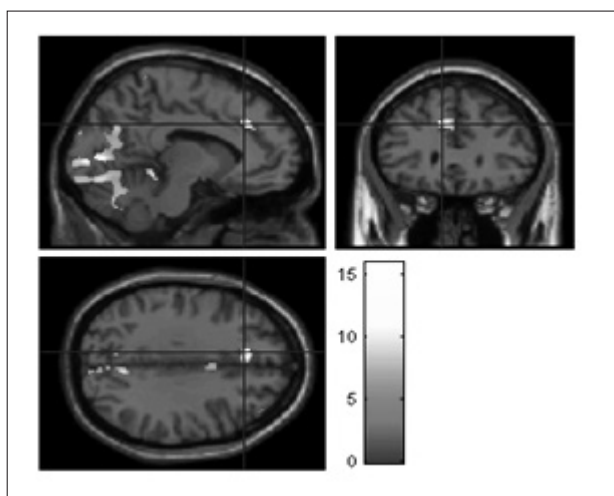


Figure 1. Statistical parametric map showing significant differences in grey matter volumes among the four groups. For illustrative purposes the map shows results for $p<0.001$, uncorrected for multiple comparisons. Only significant clusters for $p<0.05$ corrected for FWE are represented in the text. As seen in the image, the groups differ in large clusters at the level of the occipital lobe and cerebellum, as well as at the level of the medial frontal lobe.

HCs versus SCZ>10

The SCZ>10 group showed diminished volumes in left medial frontal gyrus compared to HCs ($p=0.017$ FWE, see figure 2). According to a less conservative threshold ($p\leq 0.001$), HCs showed bigger volumes compared to clinical groups in other significant clusters: left insula; right middle frontal gyrus; left para hippocampal gyrus; left superior temporal gyrus; right paracentral lobule (table 3).

HCs versus DEL

The HCs group showed grey matter volumes significantly higher than DEL group in posterior cerebral regions, as cerebellum and occipital lobes, and in frontal regions as well, particularly in the left medial frontal gyrus: these clusters resulted significant even for HCs versus SCZ>10 contrast. The following resulted significant clusters for $p<0.05$ FWE (table 3):

- a cluster of 2104 voxels, comprising the right lingual gyrus and the right and left cuneus;
- the right cerebellum pyramid;
- a cluster of 896 voxels, comprising the left lingual gyrus, the left fusiform gyrus and the left cerebellum declive;
- the left medial frontal gyrus;
- the left cerebellum uvula;
- the right cerebellum inferior semilunar lobule;
- the right precuneus.

SCZ<10 versus HCs

No cluster showed significant differences for this contrast.

SCZ<10 versus SCZ>10

No significant differences between the two SCZ groups were found for $p<0.05$ FWE. When a $p\leq 0.001$ uncorrected threshold was considered, SCZ<10 group showed bigger grey matter volumes in a cluster of 746 voxels, including the left insula and the left postcentral gyrus, and in the right para-hippocampal gyrus (table 3).

SCZ<10 versus DEL

The DEL group showed reduced grey matter volumes compared to the SCZ<10 group involving the

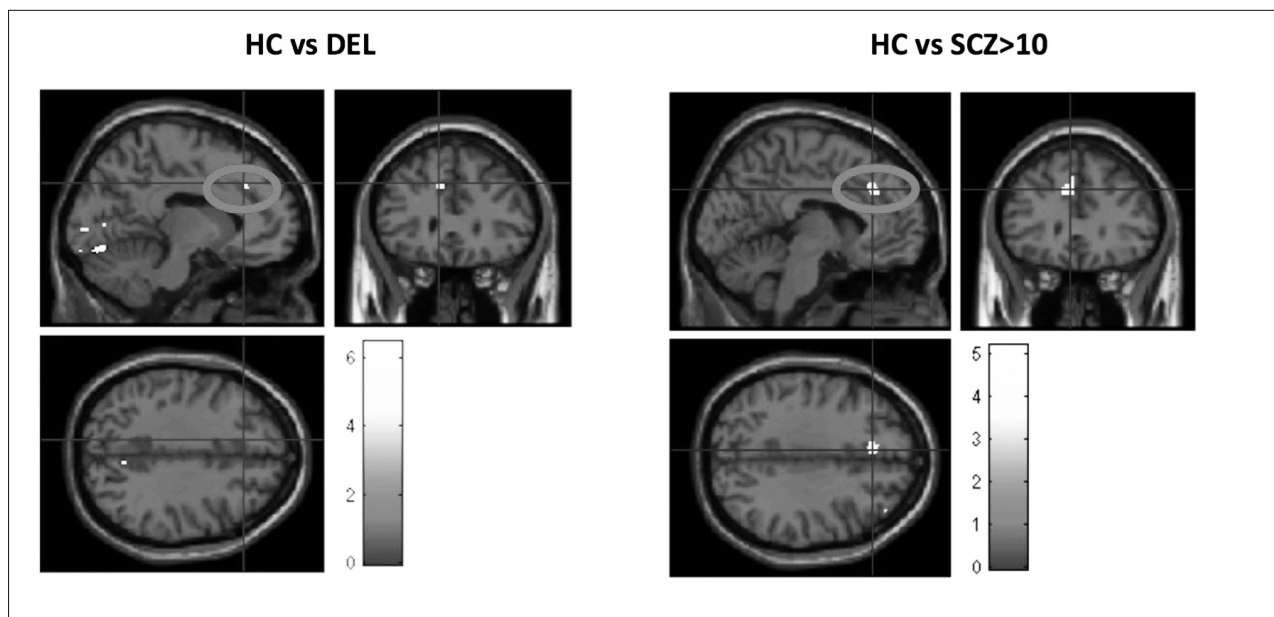


Figure 2. Statistical parametric maps showing the results of HC vs DEL and HC vs SCZ>10 SPM contrast. Both contrasts resulted significant for a reduction in the grey matter volume of the left medial frontal gyrus (grey circle in figure).

right precuneus, the left culmen, the left fusiform gyrus, the right culmen, the right cerebellum declive, the right lingual gyrus, the left cerebellum declive, the left cuneus and the left cerebellum uvula (table 3).

SCZ>10 versus HCs and SCZ>10 versus SCZ<10

No cluster showed grey matter volumes significantly greater in SCZ>10 group compared to HCs and SCZ<10 groups.

SCZ>10 versus DEL

The DEL group showed a significant reduction of grey matter volumes compared to SCZ>10 group in regard of a cluster localized in the right lingual gyrus (table 3).

DEL versus HCs; DEL versus SCZ>10; DEL versus SCZ>10

No cluster showed grey matter volumes significantly greater in DEL group compared to HCs and SCZ groups.

According to Voxel-Based Morphometry analysis, patients with SCZ>10 showed the most significant reductions of grey matter volumes in the left medial frontal gyrus, compared to HCs ($p=0.017$ FWE). The same cluster, i.e. the same MNI peak coordinates, resulted significantly decreased in DEL group compared to HCs as well ($p=0.006$ FWE) (figure 2). Volumes of Interests (VOI, $r=8\text{mm}$) were extracted for

all subjects from the peak coordinates of this cluster. Figure 3 shows results from the ANOVA comparing VOI between groups. A trend was observed for SCZ<10 group that did not reach a statistical significance. The DEL group showed wide areas of grey matter depletion in occipital lobes (involving the bilateral cuneus, the lingual and the fusiform gyri), in cerebellum (involving the pyramid, the uvula and the declive) and in parietal lobes (involving the right precuneus), compared to both HCs and SCZ<10 groups. On the contrary, few areas, namely the right lingual gyrus, were found to show significant grey matter reductions in DEL group compared to SCZ>10 group (figure 4).

Discussion

The present study investigates volume abnormalities of grey matter in individuals with 22q11.2DS without psychotic disorders compared to subjects with a diagnosis of idiopathic schizophrenia and healthy controls, through a whole-brain comparison which employed Voxel-Based Morphometry technique. In particular, the DEL group appeared to have significant reductions of grey matter compared to healthy controls, namely in occipital and parietal lobes and in the cerebellum. Similar findings were observed when comparing the DEL group with the SCZ groups, likely suggesting they are not directly associated with full-blown schizophrenia. Interestingly, in DEL

Table 3. Details of the loci resulted with a significant reduction in grey matter volume from each SPM contrast.

HCs versus SCZ<10	MNI Coordinates	K	Test statistics
R superior temporal gyrus	x=42, y=-46, z=-15	192 voxels	T=4.4, p<0.001 unc
L middle occipital gyrus	x=-42, y=-84, z=-1	6 voxels	T=3.34, p<0.001 unc
L inferior occipital gyrus	x=-41, y=-70, z=-5	5 voxels	T=3.33, p<0.001 unc
HCs versus SCZ>10			
L medial frontal gyrus	x=-11, y=32, z=34	6 voxels	T=5.2, p<0.017 FWE
L insula	x=-44, y=-15, z=19	389 voxels	T=4.52, p<0.001 unc
R middle frontal gyrus	x=42, y=42, z=33	104 voxels	T=3.65, p<0.001 unc
L parahippocampal gyrus	x=-15, y=-34, z=-0	57 voxels	T=3.59, p<0.001 unc
L superior temporal gyrus	x=-56, y=-15, z=-3	7 voxels	T=3.38, p<0.001 unc
R paracentral lobule	x=9, y=-39, z=60	27 voxels	T=3.36, p<0.001 unc
HCs versus DEL			
R lingual gyrus	x=12, y=-82, z=-12	2104 voxels	T=6.47, p<0.001 FWE
R cuneus	x=6, y=-75, z=-9		T=6.28, p<0.001 FWE
L cuneus	x=-3, y=-78, z=4		T=6.05, p<0.001 FWE
R cerebellum pyramid	x=16, y=-63, z=-29	208 voxels	T=6.05, p<0.003 FWE
L lingual gyrus	x=-12, y=-81, z=-14	896 voxels	T=5.68, p<0.004 FWE
L fusiform gyrus	x=-20, y=-70, z=-15		T=5.48, p<0.007 FWE
L cerebellum declive	x=-23, y=-66, z=-26		T=5.46, p<0.008 FWE
L medial frontal gyrus	x=-11, y=30, z=-34	20 voxels	T=5.52, p<0.006 FWE
L cerebellum uvula	x=-2, y=-67, z=-39	61 voxels	T=5.16, p<0.02 FWE
R cerebellum inferior semilunar lobule	x=21, y=-73, z=-53	215 voxels	T=5.12, p<0.022 FWE
R precuneus	x=7, y=-63, z=36	11 voxels	T=5.01, p<0.031 FWE
SCZ<10 versus SCZ>10			
L insula	x=-47, y=-15, z=18	746 voxels	T=4.59, p<0.001 unc
L postcentral gyrus	x=-57, y=-19, z=16		T=4.02, p<0.001 unc
R para-hippocampal gyrus	x=27, y=2, z=-20	82 voxels	T=3.46, p<0.001 unc
SCZ<10 versus DEL			
R precuneus	x=16, y=-81, z=47	55 voxels	T=6.35, p<0.001 FWE
L culmen	x=-14, y=-37, z=-14	207 voxels	T=6.18, p<0.001 FWE
L fusiform gyrus	x=-20, y=-70, z=-14	96 voxels	T=5.33, p<0.011 FWE
R culmen	x=10, y=-40, z=-11	45 voxels	T=4.73, p<0.013 FWE
R cerebellum declive	x=15, y=-64, z=-27	34 voxels	T=4.67, p<0.017 FWE
R lingual gyrus	x=10, y=-82, z=-11	78 voxels	T=4.65, p<0.018 FWE
L cerebellum declive	x=-33, y=-64, z=-30	87 voxels	T=4.53, p<0.029 FWE
L cuneus	x=-8, y=-87, z=1	8 voxels	T=4.94, p<0.037 FWE
L cerebellum uvula	x=-2, y=-64, z=-39	8 voxels	T=4.93, p<0.038 FWE

group a significant grey matter depletion in the left medial frontal gyrus was observed compared to both HCs and SCZ>10 groups (respectively p=0.006 FWE, p=0.017 FWE) (figure 2); our findings were in

line with previous evidence of volume abnormalities in the prefrontal structure, as the left medial frontal gyrus, representing neural correlates of an increased vulnerability to psychosis^{27,42}; indeed, functional al-

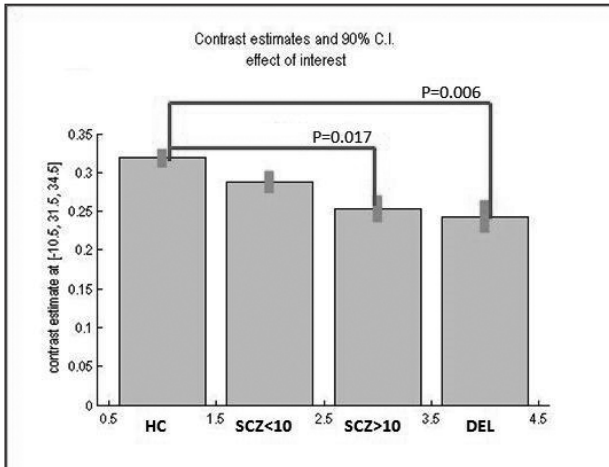


Figure 3. SPM plot showing the mean VOI extracted from the left medial frontal gyrus (MNI peak coordinates: $x=-11, y=32, z=34$) from each subject. P values represent ANOVA post hoc test results.

terations of the left medial frontal gyrus appeared to be correlated with social cognition impairments in 22q11.2DS^{43,44}, which in turn have been associated with the vulnerability to psychosis. On the other side, as previously mentioned, functional abnormalities in the left medial frontal gyrus have been associated with schizophrenia and with the duration of the illness (DOI)³⁵. The volume of the same regions appeared reduced at a trend level in the SCZ<10 group compared to HCs as well (figure 3). Despite the extensive grey matter abnormalities found in patients with 22q11.2DS, this group differed only in regard of the right lingual gyrus volume when compared to individuals with chronic schizophrenia (figure 4). It has been suggested that this neuroanatomical region plays an important role in language identification and re-

cognition, and in visual-spatial processing as well. Previous studies have reported deficits in these domains in people with 22q11.2DS⁴⁵⁻⁴⁷, which is in line with our results. To note, considering that the recruited clinical groups did not show significant differences in IQ scores, it may be suggested that the above-mentioned findings are not secondary to intellectual disability in subjects with 22q11.2DS. Given the SCZ groups did not differ in regard of symptoms' severity and dosage of antipsychotic treatment at the moment of study assessment, other factors likely interfering with observed findings should be suggested, like DOI or the cumulative dose of antipsychotics. Evidence is accumulating that the 22q11.2 microdeletion affects carriers' physiological neurodevelopment leading to neurocognitive impairments time before the psychotic symptoms' onset; with great caution we may speculate that this genetic condition would differ from idiopathic schizophrenia in regard to which other environmental factors would significantly participate to the clinical phenotype, even without the evidence of a neuroanatomical correlate.

Previous VBM based studies found that the volume reduction of the prefrontal grey matter in schizophrenia correlated with the duration of illness, as observed by comparing patients at first episode of psychosis with others with both brief and long history of illness²⁸. Moreover, the progression of brain structural alterations in schizophrenia has been associated to the course of the illness, comparing at risk individuals with both first episode cases and chronic patients: it has been proposed that the progressive grey matter reductions would develop on pre-existing neuroanatomical abnormalities which in their turn likely had influenced the vulnerability to schizophrenia. Possibly, with the evolution of the psychotic




Figure 4. Statistical parametric maps depicting how reduction in grey matter volume are more severe in DEL group when compared to HC or SCZ<10 group. Abnormalities are instead less important when 22q11.2DS subjects are compared to schizophrenic patients with a long illness duration.

disorder a volume loss in prefrontal and thalamic regions seems to be added to the ones in the anterior cingulate cortex and in the right insula, which have been reported in individuals at high risk for psychosis²⁵. Longitudinal⁴⁸ and meta-analytical⁴⁹ studies suggested a key role of antipsychotic treatments in influencing grey matter volumes, according to their typical or atypical pharmacodynamic mechanisms: it has been argued that a combination of physiopathological mechanisms and antipsychotics effects would have an impact on progressive brain changes in schizophrenia. Given the cross-sectional design of the present study, longitudinal studies are required to control the effect of cumulative antipsychotics dosage.

Overall, our findings appear in line with previous evidence about reductions in grey matter volumes in schizophrenia, involving the superior temporal gyrus, the insula, the medial frontal cortex and the para-hippocampal gyrus^{18,22,50}.

Neuroanatomical abnormalities in 22q11.2DS were observed as well³³, although to date the only meta-analysis exploring grey matter features in this syndrome was implemented on ROI (Region Of Interest) based studies, mainly on paediatric samples³². Data on structural brain imaging show that the 22q11.2DS is associated with a whole brain volume reduction, both of grey and white matter: namely the prefrontal cortex and the hippocampus are particularly involved while the corpus callosum shows higher volumes of white matter than controls. A rostro-caudal pattern has been observed for the above-mentioned brain volume loss in the syndrome, which appears more severe in adults compared to children, with a progressive course "frontal > temporal > cerebellar > occipital": it has been hypothesized that brain volume reduction in the 22q11.2DS would reflect the expression of abnormal developmental trajectories starting from early ages. The correlation between genetic vulnerability to schizophrenia and brain volume loss has been explored in 22q11.2DS, namely in a VBM study that described a significant impact of COMT polymorphisms on volumes of different brain areas as the frontal lobes, the cerebellum and the para-hippocampal gyrus⁵¹; indeed, differently from previous ROI based studies, a whole brain investigation as the one provided by VBM methodology has allowed to evidence a role of COMT polymorphisms in modulating volumes of different brain regions, probably affecting several neurotransmitters systems crucial for the neurodevelopment. Interestingly, the above-described loss of brain volumes resulted not only associated with COMT low activity but also with a higher predisposition to psychosis onset in 22q11.2DS subjects⁵². Takahashi and colleagues found that in the syn-

drome a progressive detriment in superior temporal gyrus volumes was associated with a higher risk of psychosis onset, as previously evidenced for volume loss of frontal lobes⁵³. These findings were confirmed by a Voxel-Based Morphometry study conducted in a sample of individuals with 22q11.2DS which reported the association between the diagnosis of schizophrenia and a bilateral reduction of grey matter volumes in the superior temporal gyrus³⁴.

Our findings seem to suggest that in 22q11.2DS a genetic vulnerability to schizophrenia may be somehow associated to grey matter volumes depletion, as previously evidenced for the dorsolateral prefrontal cortex, the superior temporal gyrus and the superior parietal lobule^{26,54}. Moreover, we may hypothesize that specific neurobiological alterations observed in a sample at high genetic risk for psychosis as individuals with 22q11.2DS would represent a homogeneous risk factor for the onset of a psychotic disorder: indeed the brain structural abnormalities highlighted in people with 22q11.2DS appear like those resulted in brains of patients with chronic schizophrenia, suggesting a particular biological vulnerability associated to impairments of these regions.

Bearing these considerations, in 22q11.2DS the genetic predisposition to schizophrenia appears enhanced to the extent that other environmental factors influencing the symptoms onset seem to play a minor role. Indeed, in idiopathic schizophrenia which has a multifactorial nature, its neurobiological risk factors seem to have a lower impact, likely being modulated by plastic modifications. Therefore, in patients with chronic schizophrenia the cumulative impact arising from a long course full-blown psychosis seems to particularly contribute to neuroanatomical detriment.

Limitations

The present study has several pitfalls as the low size of the sample. This drawback obliges us to cautiously interpret the volume differences between groups and the significance of the neural correlates that we have observed. However, enrolling adult patients with 22q11.2DS is particularly difficult due to the rarity of the syndrome and to the high risk of diagnosis underestimation. Another limit of the study is the lack of a comparison with a sample of patients with 22q11.2DS and psychosis or with attenuated psychotic symptoms. Another concern involved the distinction of people with schizophrenia according to the average amount of years of illness duration: such methodological approach was based on a previous study on the same sample³⁵, which demonstrated a correlation between frontal lobes abnormalities and duration of illness. The

potential bias that the SCZ group appeared heterogeneous for other confounding variables cannot be ruled out. Finally, our analysis did not investigate white matter integrity and correlations with genetic polymorphisms, for which future studies are required.

Conclusions

The present study showed broad areas of grey matter volume reduction in individuals with 22q11.2DS, namely at the level of occipital lobes and cerebellum. However, few significant differences were observed between people with 22q11.2DS without psychosis and patients with chronic schizophrenia in regard of grey matter detriment. A common area with reduced volume involving the left medial frontal gyrus was observed in both recruited clinical groups compared to healthy controls. Therefore, it can be suggested that this neuroanatomical area might be related to the neurobiological vulnerability to schizophrenia. Longitudinal studies on larger samples are needed to shed light on such an interesting hypothesis.

Conflict of interests: Tommaso Accinni has been a consultant and/or a speaker and/or has received research grants from TEVA; Martina Fanella has been a consultant and/or a speaker and/or has received research grants from Neuraxpharm, UCB Pharma; Carlo Di Bonaventura has been a consultant and/or a speaker and/or has received research grants from Eisai, UCB Pharma, FB Health, Sandoz; the other authors have no conflict of interests to declare.

References

- McDonald-McGinn DM, Sullivan KE, Marino B, et al. 22Q11.2 Deletion Syndrome. *Nat Rev Dis Prim* 2015; 1: 15071.
- Scambler PJ. The 22q11 deletion syndromes. *Hum Mol Genet* 2000; 9: 2421-6.
- Shprintzen RJ. Velo-cardio-facial syndrome: 30 Years of study. *Dev Disabil Res Rev* 2008; 14: 3-10.
- Swillen A, Vogels A, Devriendt K, Fryns JP. Chromosome 22q11 deletion syndrome: update and review of the clinical features, cognitive-behavioral spectrum, and psychiatric complications. *Am J Med Genet - Semin Med Genet* 2000; 97: 128-35.
- De Smedt B, Swillen A, Devriendt K, Fryns JP, Verschaffel L, Ghesquière P. Mathematical disabilities in children with velo-cardio-facial syndrome. *Neuropsychologia* 2007; 45: 885-95.
- Bearden CE, Woodin MF, Wang PP, Moss E. The neurocognitive phenotype of the 22q11.2 deletion syndrome: selective deficit in visual-spatial memory. *J Clin Exp Neuropsychol* 2001; 23: 447-64.
- Zinkstok J, Van Amelsvoort T. Neuropsychological profile and neuroimaging in patients with 22q11.2 deletion syndrome: a review. *Child Neuropsychol* 2005; 11: 21-37.
- Chow EWC, Watson M, Young DA, Bassett AS. Neurocognitive profile in 22q11 deletion syndrome and schizophrenia. *Schizophr Res* 2006; 87: 270-8.
- Swillen A, Devriendt K, Legius E, et al. The behavioural phenotype in velo-cardio-facial syndrome (VCFS): from infancy to adolescence. *Genet Couns* 1999; 10: 79-88.
- Murphy KC. Schizophrenia and velo-cardio-facial syndrome. *Lancet* 2002; 359: 426-30.
- Squarcione C, Torti MC, Di Fabio F, Biondi M. 22q11 deletion syndrome: a review of the neuropsychiatric features and their neurobiological basis. *Neuropsychiatr Dis Treat* 2013; 9: 1873-83.
- Schneider M, Debbané M, Bassett AS, et al. Psychiatric disorders from childhood to adulthood in 22q11.2 deletion syndrome: results from the international consortium on brain and behavior in 22q11.2 deletion syndrome. *Am J Psychiatry* 2014; 171: 627-39.
- Bassett AS, McDonald-McGinn DM, Devriendt K, et al. Practical guidelines for managing patients with 22q11.2 deletion syndrome. *J Pediatr* 2011; 159: 332-9.e1.
- Bassett AS, Chow EWC, AbdelMalik P, Gheorghiu M, Husted J, Weksberg R. The schizophrenia phenotype in 22q11 deletion syndrome. *Am J Psychiatry* 2003; 160: 1580-6.
- Gothelf D, Schneider M, Green T, et al. Risk factors and the evolution of psychosis in 22q11.2 deletion syndrome: a longitudinal 2-site study. *J Am Acad Child Adolesc Psychiatry* 2013; 52: 1192-203.e3.
- Sivagnanasundaram S, Fletcher D, Hubank M, Illingworth E, Skuse D, Scambler P. Differential gene expression in the hippocampus of the Df1/+ mice: a model for 22q11.2 deletion syndrome and schizophrenia. *Brain Res* 2007; 1139: 48-59.
- Philip N, Bassett A. Cognitive, behavioural and psychiatric phenotype in 22q11.2 deletion syndrome. *Behav Genet* 2011; 41: 403-12.
- Ellison-Wright I, Glahn DC, Laird AR, Thelen SM, Bullmore E. The anatomy of first-episode and chronic schizophrenia: an anatomical likelihood estimation meta-analysis. *Am J Psychiatry* 2008; 165: 1015-23.
- Glahn DC, Laird AR, Ellison-Wright I, et al. Meta-analysis of gray matter anomalies in schizophrenia: application of anatomic likelihood estimation and network analysis. *Biol Psychiatry* 2008; 64: 774-81.
- Dias AM, Queiroz ATL, Maracaja-Coutinho V. Schizophrenia, brain disease and meta-analyses: integrating the pieces and testing Fusar-Poli's hypothesis. *Med Hypotheses* 2010; 74: 142-4.
- Ashburner J, Friston KJ. Voxel-based morphometry - The methods. *Neuroimage* 2000; 11: 805-21.
- Bora E, Fornito A, Yücel M, Pantelis C. The effects of gender on grey matter abnormalities in major psychoses: A comparative voxelwise meta-analysis of schizophrenia and bipolar disorder. *Psychol Med* 2012; 42: 295-307.
- Fusar-Poli P, Borgwardt SJ, McGuire P (eds). *Vulnerability to psychosis: from neurosciences to psychopathology*. London: Psychology Press, 2012.
- Fusar-Poli P, Smieskova R, Serafini G, Politi P, Borgwardt S. Neuroanatomical markers of genetic liability to psychosis and first episode psychosis: a voxelwise meta-analytical comparison. *World J Biol Psychiatry* 2014; 15: 219-28.
- Chan RCK, Di X, McAlonan GM, Gong QY. Brain anatomical abnormalities in high-risk individuals, first-episode, and chronic schizophrenia: an activation likelihood estimation meta-analysis of illness progression. *Schizophr Bull* 2011; 37: 177-88.
- Cannon M, Caspi A, Moffitt TE, et al. Evidence for early-childhood, pan-developmental impairment specific to schizophreniaiform disorder: results from a longitudinal birth cohort. *Arch Gen Psychiatry* 2002; 59: 449-56.
- Fusar-Poli P, Radua J, McGuire P, Borgwardt S. Neuroanatomical maps of psychosis onset: Voxel-wise meta-analysis of antipsychotic-naïve vbm studies. *Schizophr Bull* 2012; 38: 1297-307.

28. Molina V, Sanz J, Sarramea F, Benito C, Palomo T. Lower prefrontal gray matter volume in schizophrenia in chronic but not in first episode schizophrenia patients. *Psychiatry Res* 2004; 131: 45-56.
29. Premkumar P, Kumari V, Corr PJJ, Sharma T. Frontal lobe volumes in schizophrenia: effects of stage and duration of illness. *J Psychiatr Res* 2006; 40: 627-37.
30. Tomelleri L, Jogia J, Perlini C, et al. Brain structural changes associated with chronicity and antipsychotic treatment in schizophrenia. *Eur Neuropsychopharmacol* 2009; 19: 835-40.
31. Hietala J, Cannon TD, Van Erp TGM, et al. Regional brain morphology and duration of illness in never-medicated first-episode patients with schizophrenia. *Schizophr Res* 2003; 64: 79-81.
32. Tan GM, Arnone D, McIntosh AM, Ebmeier KP. Meta-analysis of magnetic resonance imaging studies in chromosome 22q11.2 deletion syndrome (velocardiofacial syndrome). *Schizophr Res* 2009; 115: 173-81.
33. Eliez S, Blasey CM, Schmitt EJ, White CD, Hu D, Reiss AL. Velocardiofacial syndrome: are structural changes in the temporal and mesial temporal regions related to schizophrenia? *Am J Psychiatry* 2001; 158: 447-53.
34. Chow EWC, Ho A, Wei C, Voormolen EHJ, Crawley AP, Basset AS. Association of schizophrenia in 22q11.2 deletion syndrome and gray matter volumetric deficits in the superior temporal gyrus. *Am J Psychiatry* 2011; 168: 522-9.
35. Frascarelli M, Tognin S, Mirigliani A, et al. Medial frontal gyrus alterations in schizophrenia: relationship with duration of illness and executive dysfunction. *Psychiatry Res* 2015; 231: 103-10.
36. Wechsler D. WAIS-R : manual: Wechsler adult intelligence scale--revised. New York: Harcourt Brace Jovanovich [for] Psychological Corp., 1981.
37. Kay SR, Fiszbein A, Opler LA. The positive and negative syndrome scale (PANSS) for schizophrenia. *Schizophr Bull* 1987; 13: 261-76.
38. Jones SH, Thornicroft G, Coffey M, Dunn G. A brief mental health outcome scale. Reliability and validity of the global assessment of functioning (GAF). *Br J Psychiatry* 1995; 166: 654-9.
39. Ashburner J. A fast diffeomorphic image registration algorithm. *Neuroimage* 2007; 38: 95-113.
40. Yassa MA, Stark CEL. A quantitative evaluation of cross-participant registration techniques for MRI studies of the medial temporal lobe. *Neuroimage* 2009; 44: 319-27.
41. Mechelli A, Friston KJ, Frackowiak RS, Price CJ. Structural covariance in the human cortex. *J Neurosci* 2005; 25: 8303-10.
42. Harms MP, Wang L, Campanella C, et al. Structural abnormalities in gyri of the prefrontal cortex in individuals with schizophrenia and their unaffected siblings. *Br J Psychiatry* 2010; 196: 150-7.
43. Larsen KM, Dzafic I, Siebner HR, Garrido MI. Alteration of functional brain architecture in 22q11.2 deletion syndrome - Insights into susceptibility for psychosis. *Neuroimage* 2019; 190: 154-71.
44. Schneider M, Debbané M, Lagioia A, Salomon R, D'Argembeau A, Eliez S. Comparing the neural bases of self-referential processing in typically developing and 22q11.2 adolescents. *Dev Cogn Neurosci* 2012; 2: 277.
45. Solot CB, Sell D, Mayne A, et al. Speech-language disorders in 22q11.2 deletion syndrome: best practices for diagnosis and management. *Am J Speech-Language Pathol* 2019; 28: 984-99.
46. Moss EM, Batshaw ML, Solot CB, et al. Psychoeducational profile of the 22q11.2 microdeletion: a complex pattern. *J Pediatr* 1999; 134: 193-8.
47. Buzzanca A, Accinni T, Frascarelli M, et al. Recognition of facial emotion expressions and perceptual processes in 22q11.2 deletion syndrome. *Early Interv Psychiatry* 2022; doi:10.1111/EIP.13295.
48. Ho BC, Andreasen NC, Ziebell S, Pierson R, Magnotta V. Long-term antipsychotic treatment and brain volumes: A longitudinal study of first-episode schizophrenia. *Arch Gen Psychiatry* 2011; 68: 128-37.
49. Fusar-Poli P, Smieskova R, Kempton MJ, Ho BC, Andreasen NC, Borgwardt S. Progressive brain changes in schizophrenia related to antipsychotic treatment? A meta-analysis of longitudinal MRI studies. *Neurosci Biobehav Rev* 2013; 37: 1680-91.
50. Agnew-Blais J, Seidman LJ. Neurocognition in youth and young adults under age 30 at familial risk for schizophrenia: a quantitative and qualitative review. *Cogn Neuropsychiatry* 2013; 18: 44-82.
51. Van Amelsvoort T, Zinkstok J, Figuee M, et al. Effects of a functional COMT polymorphism on brain anatomy and cognitive function in adults with velo-cardio-facial syndrome. *Psychol Med* 2008; 38: 89-100.
52. Gothelf D, Schaer M, Eliez S. Genes, brain development and psychiatric phenotypes in velo-cardio-facial syndrome. *Dev Disabil Res Rev* 2008; 14: 59-68.
53. Takahashi T, Wood SJ, Yung AR, et al. Progressive gray matter reduction of the superior temporal gyrus during transition to psychosis. *Arch Gen Psychiatry* 2009; 66: 366-76.
54. Moran ME, Pol HH, Gogtay N. A family affair: brain abnormalities in siblings of patients with schizophrenia. *Brain* 2013; 136: 3215-26.

Corresponding author:
Dr. Tommaso Accinni
Department of Human Neurosciences
Sapienza University of Rome
Piazzale Aldo Moro 5
00185 Rome, Italy
E-mail: tommaso.accinni@uniroma1.it; tommasoaccinni@gmail.com.